

EQUINE PITUITARY PARS INTERMEDIA DYSFUNCTION (PPID):
PATHOPHYSIOLOGY AND A SURGICAL APPROACH TO TREATMENT

A Thesis Submitted to the College of
Graduate and Postdoctoral Studies
In Partial Fulfillment of the Requirements
For the Degree of Doctor of Philosophy
In the Department of Veterinary Pathology
University of Saskatchewan
Saskatoon

By

JAMES LAWRENCE CARMALT

© Copyright James Carmalt, June, 2017. All rights reserved.

PERMISSION TO USE

In presenting this thesis in partial fulfilment of the requirements for a Postgraduate degree from the University of Saskatchewan, I agree that the Libraries of this University may make it freely available for inspection. I further agree that permission for copying of this thesis in any manner, in whole or in part, for scholarly purposes may be granted by the professor or professors who supervised my thesis work or, in their absence, by the Head of the Department or the Dean of the College in which my thesis work was done. It is understood that any copying or publication or use of this thesis or parts thereof for financial gain shall not be allowed without my written permission. It is also understood that due recognition shall be given to me and to the University of Saskatchewan in any scholarly use which may be made of any material in my thesis.

Requests for permission to copy or to make other use of material in this thesis in whole or part should be addressed to:

Head of the Department of Veterinary Pathology

University of Saskatchewan

Saskatoon, Saskatchewan S7N 5B4

ABSTRACT

Equine pituitary pars intermedia dysfunction (PPID) is a common endocrine disease of the older horse. First described in 1932, and likened to human Cushing's disease, it is associated with an enlargement of the pituitary gland that was classically termed an adenoma. The underlying mechanism is attributable to a lack of dopaminergic inhibition of the pars intermedia. Treatment methods have remained essentially unchanged for 30 years and the prevalence data have mainly stemmed from Eastern Australia and the USA. The general objective of this thesis was to explore the feasibility of developing a targeted cell-specific approach for the treatment of equine PPID. The specific aims were to confirm the need for this advanced therapy by determining the prevalence of PPID in horses globally; to continue the investigation of the underlying cellular mechanism of PPID by confirming the role of pro-hormone convertases, and sequence the equine pro-opiomelanocortin, prohormone convertase 1 and 2 genes; and to investigate the methodology for site-specific applications of future therapy for equine PPID. These aims were met by reporting the prevalence data from a worldwide audience of veterinarians using an internet-based survey tool; by describing partial gene sequences of the equine proopiomelanocortin and prohormone convertase enzymes and their expression in normal and PPID horses; and by showing how low-volume contrast enhancement of the brain using computed tomography can delineate the margins of the pituitary gland, showing how general anesthesia affects the pulsatility and concentration of adrenocorticotrophic hormone, and finally, modifying a previously reported technique, by developing a novel surgical approach to the treatment of this classical condition.

ACKNOWLEDGMENTS

I would like to acknowledge the guidance received from my supervisor (Dr. Andrew Allen) and my Advisory Committee members. All of the manuscripts contained within this thesis are the work of multiple authors whose editorial input was essential in the acceptance of the work by our peers. The help and support of Drs. Hal Schott II and Han van der Kolk in introducing me to the ventral cavernous sinus catheter technique and supplying some samples used for the hormone assays was invaluable. I am also grateful for laboratory assistance from Mrs. Susan Cook, Mrs. Kim Tran and Ms. Sima Mortazavi, and for funding from the Townsend Equine Health Research Fund at the Western College of Veterinary Medicine.

DEDICATION

The work in this thesis is dedicated to the veterinary profession and our equine patients.

Additionally, I would like to dedicate my work to mentors, who from an early age developed and nurtured an interest in the veterinary profession. Mrs. Janet Keymer taught junior school Biology and together with her husband, Dr. Ian Keymer, put on trips to zoos across the United Kingdom. Dr. Keymer, a consultant veterinary pathologist, managed to get “behind the scenes” access in most places which was fascinating and engendered a strong belief in understanding the pathophysiological basis of veterinary disease.

The late Dr. “Tim” Cheyne was a retired Royal Veterinary College lecturer, who had worked for the Overseas Development Agency in the United Kingdom and after travelling the world, ended up in Qatar. He supervised a school project for a geography class, which was based on the effect of extreme climates on milk production in dairy cattle. He was unstinting in his efforts to source weather data and provided milk records for the dairy company, which may have otherwise been unavailable. He remained a friend and mentor until his death in 2013.

Finally and most importantly, I could not have completed this work without the love and support of my family. I think, at times, I forgot the effect that a body of work of this nature has on the other members of a family unit. Thank you.

TABLE OF CONTENTS

	<u>Page</u>
PERMISSION TO USE	i
ABSTRACT	ii
ACKNOWLEDGMENTS	iii
DEDICATION	iv
LIST OF TABLES	viii
LIST OF FIGURES	iix
CHAPTER ONE - LITERATURE REVIEW	1
1.1 Introduction.....	2
1.2 Anatomy.....	4
1.3 Physiology.....	6
1.4 Pathophysiology.....	8
1.5 Clinical Signs.....	11
1.6 Diagnostic Tests.....	16
1.6.1 Hormone Concentrations.....	16
1.6.2 Imaging.....	23
1.6.3 Necropsy.....	25
1.7 Treatment.....	26
1.7.1 Medical.....	26
1.7.2 Surgical.....	28
1.8 General Objectives and Specific Aims.....	31
1.9 References.....	32
CHAPTER TWO - EQUINE PITUITARY PARS INTERMEDIA DYSFUNCTION: AN INTERNATIONAL SURVEY OF VETERINARIANS' APPROACH TO DIAGNOSIS, MANAGEMENT AND ESTIMATED PREVALENCE	53
Transition Page.....	54
2.1 Abstract.....	56
2.2 Introduction.....	57
2.3 Materials and Methods.....	58
2.4 Results.....	60
2.5 Discussion.....	66
2.6 References.....	74

CHAPTER THREE - PROFILES OF PRO-OPIOMELANOCORTIN AND ENCODED PEPTIDES AND THEIR PROCESSING ENZYMES IN EQUINE PITUITARY PARS INTERMEDIA DYSFUNCTION 80

Transition Page	81
3.1 Abstract	83
3.2 Introduction	84
3.3 Materials and Methods	85
3.3.1 Animals	85
3.3.2 Total RNA Extraction and cDNA Synthesis	86
3.3.3 Primers	87
3.3.4 RT-PCR and Sequencing	87
3.3.5 RT-Quantative PCR	89
3.3.6 Hormone Measurements	90
3.3.7 Statistical Analysis	91
3.4 Results	91
3.5 Discussion	107
3.6 References	111

CHAPTER FOUR - INTRA-ARTERIAL INJECTION OF IODINATED CONTRAST MEDIUM FOR CONTRAST ENHANCED COMPUTED TOMOGRAPHY OF THE EQUINE HEAD 114

Transition Page	115
4.1 Abstract	117
4.2 Introduction	118
4.3 Materials and Methods	120
4.4 Results	124
4.5 Discussion	129
4.6 References	134

CHAPTER FIVE - EFFECTS OF ANESTHESIA WITH ISOFLURANE ON PLASMA CONCENTRATIONS OF ADRENOCORTICOTROPIC HORMONE IN SAMPLES OBTAINED FROM THE CAVERNOUS SINUS AND JUGULAR VEIN OF HORSES 137

Transition Page	138
5.1 Abstract	140
5.2 Introduction	141
5.3 Materials and Methods	144
5.4 Results	149
5.5 Discussion	151
5.6 References	160

CHAPTER SIX - DEVELOPMENT OF A NOVEL SURGICAL APPROACH TO THE TREATMENT OF PITUITARY PARS INTERMEDIA DYSFUNCTION IN THE HORSE	166
Transition Page	167
6.1 Abstract	169
6.2 Introduction.....	170
6.3 Materials and Methods.....	172
6.3.1 Myeloscopic Approach	172
6.3.2 Trans-Sphenopalatine Sinus Approach.....	173
6.3.3 Ventral Trans-Basisphenoidal Osteotomy Approach.....	174
6.3.4 Intravenous (Minimally Invasive) Approach	177
6.4 Results.....	186
6.5 Discussion.....	187
6.6 References.....	195
 CHAPTER SEVEN - GENERAL DISCUSSION	 202
7.1 Introduction.....	202
7.2 General Results and Future Studies	203
7.3 Conclusions.....	208
7.4 References.....	209
 APPENDIX A - PAPER AND ONLINE QUESTIONNAIRE CIRCULATED TO DETERMINE VETERINARIAN APPROACH TO DIAGNOSIS, MANAGEMENT AND REPORTED PREVALENCE	 212
 APPENDIX B - LIST OF GENERAL AND EQUINE VETERINARY MEDICAL GROUPS PASSING THE SURVEY LINK TO THEIR EMAIL LISTS, POSTED A LINK ON THEIR WEB PAGES OR SENDING THE LINK IN NEWSLETTERS	 215

LIST OF TABLES

<u>Table</u>	<u>Page</u>
1.1 Reported prevalence of equine pituitary pars intermedia dysfunction.....	3
2.1 Number of veterinary responses tabulated by country and grouped by geographical region.....	61
2.2 Distribution of respondents by practice categories	63
2.3 Distribution of respondents by practice type.....	63
3.1 Sequences of primers, gene bank accession number, amplicon size, and annealing temperature used for RT-PCR and RT-qPCR	88
4.1 Unconditional analysis of potential factors on soft tissue attenuation measured in Hounsfield units.....	125
4.2 Final multivariable model of factors affecting soft tissue attenuation measured in Hounsfield units.....	126
5.1 Summary of specific physiological data collected for 6 horses during general anesthesia	150
5.2 Mean plasma ACTH concentrations (pg/mL) at varying time points (minutes) illustrating differences between standing position (S) and general anesthesia (A), and between peripheral (P) and cavernous sinus (C) blood.....	152
5.3 Outcome of deconvolution analysis, standing and under isoflurane anesthesia	154

LIST OF FIGURES

<u>Figure</u>	<u>page</u>
3.1A Equine POMC partial amino acid sequence compared to predicted <i>Equus caballus</i> and <i>Homo sapiens</i> sequences	92
3.1B Equine PC1 partial amino acid sequence compared to predicted <i>Equus caballus</i> and <i>Homo sapiens</i> sequences	93
3.1C Equine PC2 partial amino acid sequence compared to predicted <i>Equus caballus</i> and <i>Homo sapiens</i> sequences	94
3.2A Cycle threshold (Ct) values for all 9 internal control genes in the equine pituitary gland	96
3.2B Cycle threshold (Ct) values for the mRNA expression of 18S rRNA in the pituitary gland of normal (n = 10) and PPID (n = 10) horses	97
3.2C Cycle threshold (Ct) values for the mRNA expression of YWHAZ in the pituitary gland of normal (n = 10) and PPID (n = 10) horses	98
3.3A A RT-PCR gel electrophoresis image showing the expression of equine POMC, PC1, and PC2 in the pituitary gland	99
3.3B POMC mRNA expression in the equine pituitary gland tissue from normal (n = 10) and PPID (n = 6) horses	100
3.3C PC1 mRNA expression in the equine pituitary gland tissue from normal (n = 10) and PPID (n = 6) horses	101
3.3D PC2 mRNA expression in the equine pituitary gland tissue from normal (n = 10) and PPID (n = 6) horses	102
3.4A Plasma concentrations of POMC in the plasma of ventral cavernous sinus blood of normal (n = 6) and PPID (n = 6) horses	103
3.4B Plasma concentrations of ACTH in the plasma of ventral cavernous sinus blood of normal (n = 6) and PPID (n = 6) horses	104
3.4C Plasma concentrations of α MSH in the plasma of ventral cavernous sinus blood of normal (n = 6) and PPID (n = 6) horses	105
3.4D Plasma concentrations of CLIP in the plasma of ventral cavernous sinus blood of normal (n = 6) and PPID (n = 6) horses	106

4.1	Axial CT slices of the same horse at the same level of the pituitary gland	128
6.1	A photograph of the brain and caudal nasal passages of an equine cadaver head.....	176
6.2	A cadaver dissection showing the position of the vein, artery and parotid salivary duct (yellow arrow) in a mature horse. Rostral is to the left.	178
6.3A	Placement of the Swan-Ganz catheter in the left deep facial vein. Rostral is to the left.	179
6.3B	A cadaver dissection showing the catheter advanced via the right deep facial vein into the orbital fissure. Rostral is to the right.*	180
6.4	A cadaver dissection, showing the placement of the 7FG Swan-Ganz catheter in the ventral cavernous sinus of the brain having entered via the orbital fissure*	181
6.5A	A dorso-ventral fluoroscopic image of the cranium showing the catheter tip (arrows) adjacent to the pituitary gland (not visible).....	183
6.5B	A dorso-ventral fluoroscopic image of the cranium showing the contrast flow in the ventral cavernous sinus around a central filling defect which represents the pituitary gland	184
6.6	A dorso-ventral subtraction angiographic image of the cranium showing the catheter (X), needle placement within the pituitary gland (white arrow), "tumor blush" (delineated by arrows) around the needle, and extra contrast material filling the ventral cavernous sinus after injection	185

CHAPTER 1

LITERATURE REVIEW

1.1 INTRODUCTION

Equine pituitary pars intermedia dysfunction (PPID), also known as equine Cushing's disease, was first described in 1932 (Pallaske 1932). It is a common endocrine disease of older horses, frequently co-diagnosed with equine metabolic syndrome (EMS; Donaldson et al. 2004; Karikoski et al. 2011; Ireland et al. 2013; Welsh 2016). Clinical signs are typically noted in horses older than 15 years and are rare in horses under 10 years old (Orth et al. 1982; Schott 2002).

The reported prevalence of disease is varied and depends greatly on the population of horses, and the methods used to diagnose the condition (Table 1.1). It varies from 0.025% of all horses in a hospital population, to 39% in a study that focused on a small number of aged horses. There does not appear to be a sex predisposition, despite early reports to the contrary (McFarlane 2011). This difference may reflect the fact that female horses could have been kept to an older age due to their breeding potential, whereas castrated males (geldings) may have been euthanased at an earlier age, confounding the sex-effect. Ponies and Morgan horses were thought to be predisposed to the development of PPID (McFarlane 2011). However, an Australian study of 340 aged horses (McGowan 2013) found that while ponies were older, there was not a breed or height significance associated with the diagnosis of PPID. Additionally, the disease has been reported in other equid species, such as donkeys and onagers (Peel et al. 2009).

Table 1.1 Reported prevalence of equine pituitary pars intermedia dysfunction.

First Author	Publication Year	Case Definition	Population (Study Duration)	N	Age (Years)	Location	Prevalence (%)
Evans	1972	Not stated	Practice	4000	All ages	USA	0.075 - 0.15 Estimated
van der Kolk	1993	Hirsutism and endogenous ACTH	Hospital (1 year)	1800	All ages	Netherlands	0.5
Mellor	2001	Not stated	Owner Questionnaire	1230	All ages	UK	< 1
Chandler	2001	Clinical examination and DST	Hospital (4 months)	23	26.5 (median)	UK	39
Brosnahan	2003a	Hirsutism or endogenous ACTH or Necropsy	Hospital (10 Years)	467	All horses > 20 > 30	USA	0.36 10 19
Brosnahan	2003b	Veterinarian Diagnosed	Owner Questionnaire	218	> 20	USA	8
Ireland	2011	Shedding / moulting changes “Cushing’s Syndrome”	Owner Questionnaire	918	> 15	UK	12.5 3.3
Rohrbach	2012	Hirsutism DST DST / TRH stimulation	Hospital 11 Years 1993 2002	134,632	All ages	USA	0.16 0.025 0.37
Ireland	2013	Not stated	Owner Questionnaire	797	All ages	UK	2.8
McGowan	2013	Hair coat changes	Owner Questionnaire	339	> 15	Australia	14
McGowan	2013	Endogenous ACTH Test	Horses from above study	325	> 15	Australia	21.2
Welsh	2016	Not stated	Multi-hospital Records 26 Years	70477	All ages	UK	2.9

Cushing's disease in canine and human patients can be either pituitary-dependent or pituitary-independent depending on the source of the endocrine abnormality. In the former case there is an over secretion of adrenocorticotrophic hormone (ACTH) by a benign, but functional, adenoma of the pars distalis of the pituitary gland. This acts on the adrenal glands and stimulates an over secretion of cortisol. The resultant clinical signs and homeostatic disturbances are a result of this elevated serum cortisol. In pituitary independent Cushing's disease, the abnormality resides wholly within the adrenal glands with the same resultant effects. Equine Cushing's disease, or PPID, differs from both of the aforementioned conditions in that while it is almost exclusively the result of hyperplasia and hypertrophy of the pars intermedia of the pituitary gland, the resulting hormonal disturbance is a result of increased circulating levels of proopiomelanocortin (POMC) peptides with only a minority of horses having adrenal hyperplasia and increased circulating serum cortisol.

1.2 ANATOMY

The pituitary gland lies within a bony depression (the sella turcica) of the basisphenoid bone at the base of the cranium. It is dorsoventrally flattened (along the long-axis) in the horse such that it lies almost parallel to the hypothalamic base in the midbrain. Separated from the rest of the brain by a thick fold of dura mater (the diaphragma sella) there is a foramen through which the infundibular stalk is attached to the hypothalamus.

There are 2 major divisions of the pituitary gland associated with its embryological development. The anterior pituitary, or the adenohipophysis, originates from an invagination of the pharyngeal

epithelium, called Rathke's pouch. It is comprised of 3 lobes, the pars distalis, the pars tuberalis and the pars intermedia. The posterior pituitary, or neurohypophysis, is composed of the pars nervosa, an outgrowth of neural tissue from the hypothalamus (Hall 2011). The pars nervosa is comprised of axons and nerve terminals originating in the paraventricular and supraoptic nuclei of the hypothalamus which stores and releases hormones oxytocin and arginine vasopressin (also known as anti-diuretic hormone).

The pars distalis is comprised of corticotrophs (producing ACTH); somatotrophs (growth hormone); lactotrophs (prolactin); thyrotrophs (thyroid stimulating hormone) and gonadotrophs (lutensising hormone and follicular stimulating hormone). The pars tuberalis, which surrounds the infundibular stalk, contains cells expressing melatonin receptors on their surface, the relative density of which changes in relation to daylight length. These bind melatonin produced by the pineal gland under the direction of the suprachiasmatic nucleus of the hypothalamus which, in turn, is influenced by the retinohypothalamic tract from the retinal ganglion cells. The cells subsequently regulate the production and release of reproductive hormones from the pars distalis (Masson-Pevet et al. 1994; Revel et al. 2009). The melanotrophs are the sole endocrine cell of the pars intermedia (McFarlane 2011). These produce α -melanocyte stimulating hormone (α MSH), β -endorphin, ACTH, corticotropin-like intermediate hormone (CLIP), and other POMC peptides, all of which are derived from POMC.

The vascular anatomy of the equine hypophysis, excluding the pars intermedia, has been described in depth (Vitums 1975). The internal carotid artery gives rise to the rostroventral infundibular (hyophyseal) arteries supplying the ventral capillary network of the median

eminence of the hypothalamus. Ventral and dorsal hypophyseal vessels descend through the pars tuberalis to supply blood to the distal part of the adenohypophysis terminating in the sinusoidal network of the pars distalis. The right and left caudal infundibular arteries arise from the caudal intercarotid artery (and in some cases the internal carotid artery) and, running in a sheath of dura mater, pass through the intercavernous sinus to become a capillary network in the most distal aspect of the pars nervosa (and infundibular stalk).

Venous drainage is caudal to the left and right cavernous sinuses. There are 2 paths, caudoventrally into the ventral petrosal sinus and foramen lacerum and, secondly, rostrolaterally exiting via the orbital fissure into the ophthalmic vein and then the deep facial vein (Vitums 1978). The latter course gives rise to an exquisite method of assessing equine hypophyseal hormone production (Irvine et al. 1984; Irvine et al. 1987; Alexander et al. 1996).

1.3 PHYSIOLOGY

The physiology of the hypophysis is controlled by the hypothalamus. There are a number of hypothalamic releasing and inhibiting hormones produced in a myriad nuclei (Hurcombe 2011). The corticotrophs (producing POMC and subsequently, ACTH) are stimulated by corticotrophin-releasing hormone produced in the parvocellular neurons in the paraventricular nucleus of the hypothalamus. The somatotrophs (producing growth hormone) are stimulated by growth hormone-releasing hormone produced in the arcuate nucleus and thyrotrophin releasing hormone (TRH) from the paraventricular nucleus of the hypothalamus. The latter hormone also stimulates the corticotrophs. Negative feedback results in the production of somatostatin (also known as

GH-inhibiting hormone) in the hypothalamus. The lactotrophs (producing prolactin) are stimulated by TRH and inhibited by dopamine produced in the tuberoinfundibular neurons of the arcuate nucleus of the hypothalamus (Hurcombe 2011). The thyrotrophs (producing thyroid stimulating hormone) are stimulated by TRH. The gonadotrophs (producing luteinising hormone and follicular stimulating hormone) are stimulated by gonadotrophin-releasing hormone produced in the preoptic nucleus of the hypothalamus.

In contrast, the melanotrophs of the pars intermedia are stimulated by TRH (as above) promoting the synthesis and secretion of POMC and the derived peptides. Melanotrophs are under the tonic, inhibitory control of dopamine secreted by dopaminergic neurons located in the periventricular nucleus of the hypothalamus. The axons transit the infundibular stalk, terminating on the melanotrophs, releasing the dopamine to bind to type-2 dopamine receptors (D2R) in the pars intermedia.

POMC produced by both the corticotrophs of the pars distalis and the melanotrophs of the pars intermedia undergoes further modification by 2 distinct pro-hormone convertase enzymes, PC1 and PC2, under dopaminergic control. PC1 is expressed in both melanotrophs and corticotrophs of the pars intermedia, where POMC is converted to ACTH. PC2, which converts ACTH to α MSH and CLIP, is expressed in the melanotrophs alone. In the unaffected horse (non-PPID) the presence of PC2 in the melanotrophs will modify any ACTH produced by PC1 (from POMC) into α MSH and CLIP. Therefore, the majority of ACTH in normal horses will be a product of the pars distalis and α MSH and CLIP will be products of the pars intermedia (Wilson et al. 1982).

1.4 PATHOPHYSIOLOGY

The underlying etiology of equine PPID is a specific expansion of the melanotrophs of the pars intermedia of the pituitary gland (McFarlane et al. 2005). These changes have been variably reported as hyperplasia, hypertrophy and classically, as a neoplasm in the form of an adenoma.

Melanotrophic expansion could occur as a result of over stimulation with TRH, or a lack of dopaminergic inhibition. Hypothalamic TRH stimulates multiple cell lines in the pars distalis as well as the melanotrophs of the pars intermedia and, so, hypersecretion of TRH should result in multiclonal expansion; however, this does not occur (Korbonits et al. 2004). TRH from the paraventricular nucleus is released into the blood vessels of the median eminence to bind to its cellular targets in the pars distalis (Hurcombe 2011). In contrast, the mechanism by which TRH reaches the melanotrophs, in the relatively poorly vascularized pars intermedia is unknown. It is, therefore, theoretically possible that this difference in delivery mechanism could result in monoclonal expansion of the melanotrophs.

A lack of dopamine inhibition could also result in multiclonal expansion. However, as the dopamine producing neuronal cell bodies of the lactotrophs are located in the arcuate nucleus and those of the melanotrophs are in the periventricular nucleus, a highly specific regional loss of these dopamine producing cells may explain the monoclonal expansion of the melanotrophs.

Indeed, there is now good evidence that PPID is a neurodegenerative disorder characterized by a lack of dopaminergic input to the melanotrophs of the pars intermedia (McFarlane 2007).

Abnormalities in both the absolute and relative abundance of POMC-derived peptides normalize

in the presence of the dopamine agonist, pergolide mesylate, resulting in subsequent improvement in clinical signs and diagnostic test results of PPID affected horses (Orth et al. 1982). Tissue from the pars intermedia of PPID horses has been reported to contain 8 times less dopamine, and 6-times less dopaminergic nerve terminals than that from aged-matched controls (Millington et al. 1998). Additionally, the periventricular nucleus of the hypothalamus in PPID horses contains 50% less dopaminergic neuronal cell bodies than age-matched control horses (McFarlane et al. 2005). These findings complement earlier cell culture research suggesting that POMC mRNA expression and the amount of immunoreactive β -endorphin was reduced in the face of a specific D2R agonist (quinpirole; Gehlert et al. 1988). Additionally, in a sheep model using hypothalamic-pituitary disconnected ewes, researchers found that without hypothalamic input, plasma levels of ACTH and cortisol rose. This led them to conclude that there was some tonic inhibitory input from the hypothalamus which was removed in their disconnect sheep, compared to those with intact hypothalamic-pituitary axes (Engler et al. 1990). It is interesting to note that these researchers discounted dopamine as the inhibitory agent based on a lack of effect on basal or stimulated ACTH production. However, the researchers were applying the dopamine treatments to the anterior pituitary and not the intermediate pituitary in this experiment. Goudreau et al. (1992) disconnected the periventricular nucleus from the pituitary gland in a rat model and found that the levels of plasma α MSH increased. These same researchers electrically stimulated the periventricular nucleus of the hypothalamus in rats with intact hypothalamic-pituitary axes and found that the plasma concentration of α MSH decreased.

Studies in dopamine receptor deficient mice have resulted in the pituitary hyperplasia (Saiardi et al. 1997). Concurrently, PC upregulation occurs, however, PC1 increases in activity by 4 to 5

times whereas that of PC2 increases by only 2 to 3 times (Saiardi et al. 1998). This differential activity would result in an overabundance of ACTH and a relative failure of further conversion into the downstream products, i.e., α MSH and CLIP.

The underlying mechanism for a lack of dopaminergic control is not known. However, there is a suggestion that oxidative stress plays a significant role. There is a significant increase in the amount of 3-nitrotyrosine (an oxidative stress marker) present in the periventricular nucleus of the hypothalamus in PPID horses compared to normal horses (McFarlane et al. 2005). Additionally, lipofuscin (a pigment associated with oxidized cell debris) has been found in the pars nervosa and the inter-septal tissues separating melanotroph clusters in the pars intermedia of PPID horses (Glover et al. 2009); both of these corresponding to the position of periventricular neurons from the hypothalamus (Saland 2001). Further, as has been found in human Parkinson's disease patients, the amount of α -synuclein has been found to be increased in PPID horses, when compared to normal horses (McFarlane et al. 2005). α -synuclein is a natural protein that accumulates by either increased production or reduced clearance (misfolding and aggregation) causing cell death.

There are 11 dopaminergic cell groups and 4 main pathways in the brain. So far, only the periventricular nuclear neuronal cell bodies have been reported to have been examined for a dopamine lack in the horse. Therefore, it is unknown whether PPID represents a dopaminergic defect solely of the periventricular nucleus or whether the other pathways are also affected. The substantia nigra has been examined (McFarlane, personal communication) and found to contain normal numbers of dopamine neuronal cell bodies. It is possible that the privileged position of

the pituitary gland (outside the blood-brain barrier) allows for the access of environmental toxins, or other agents, resulting in the selective destruction of the periventricular dopamine producing nuclei via the tuberoinfundibular pathway.

Irrespective of the underlying etiology, the melanotrophic cell line expansion results in the overproduction and systemic release of POMC and its downstream peptides resulting in the myriad clinical signs associated with PPID in the horse.

1.5 CLINICAL SIGNS

Hirsutism (more correctly termed hypertrichosis, see below) is the most unique and frequent clinical sign in the horse occurring in 55% to 80% of horses with PPID. Horses typically present with long, shaggy, or curly, hair coats that have failed to shed normally after winter. Other early signs may include longer hair in the jugular groove or distal limbs. The pathogenesis of this abnormality is unknown, however, theories include an increased androgen secretion from adrenal tissue (as seen in women with human Cushing's disease) and a dysfunction in thermoregulation at the level of the hypothalamus. While pituitary compression is cited, there is no evidence to support this theory. There is, however, evidence that age-related oxidative stress occurs in the hypothalamic-pituitary axis of rats (Kobayashi et al. 2009) and it is possible that the elevated levels of 3-nitrotyrosine (an oxidative stress marker) present in the periventricular nucleus of the hypothalamus in PPID horses, as noted by McFarlane (2005), have an unknown effect on the thermoregulatory mechanisms of this critical region of the brain. Yet another possibility is that

abnormal concentrations, or inappropriate temporal relationships between prolactin and other hormones may be responsible for hair retention in PPID (Thompson et al. 1997a and b).

Irrespective of the pathogenesis, a recent publication (Innerra et al. 2013) has reported that horses suffering from PPID did not have an increased total number of hair follicles in skin biopsy samples compared to age and sex-matched normal horses. Rather, the hirsutism was a function of a greater number of hair follicles in the resting stage, resulting in a failure to shed the hair shaft. This led the researchers to suggest that the term hirsute is not correctly applied to PPID horses and that hypertrichosis would be a more appropriate term. Older, hirsute horses are 5-times more likely to have a positive PPID test result than similarly aged animals without hair coat abnormalities (McGowan 2008). The positive predictive value (PPV) of this clinical sign in the diagnosis of the disease condition is heavily dependent on the prevalence of the condition in the population under examination. Frank et al. (2006) reported a PPV of 90% in a population of horses that had been selected for having hairy coats (PPID prevalence of 62%), whereas McGowan et al. (2013) reported a PPV of only 33% in an unselected population of horses subsequently determined to have PPID based on having elevations in seasonally-adjusted endogenous ACTH values. The prevalence of the condition in this population of horses was 21.2%. Schott et al. (2017) reported on the reliability of a clinical scoring system for PPID. These researchers used 5 clinical signs (hypertrichosis, hyperhidrosis, polyuria and polydipsia, abnormal fat deposition and muscle wasting) in addition to an elevated basal ACTH concentration or an abnormal dexamethasone suppression test. The outcome of this study was that hypertrichosis was useful to differentiate between PPID and normal horses, but that a more

detailed scoring system needed more investigation. Other causes of hypertrichosis (or hirsutism) in the horse are rare. There are isolated case reports of iatrogenic adrenal insufficiency associated with anabolic steroid treatment (Dowling et al. 1993), a functioning adrenocortical tumor (van der Kolk et al. 2001), and a case of pituitary lymphoma (Mitsui 2007) that have been reported as causing abnormal hair coats or abnormal shedding profiles in horses.

Chronic, recurrent laminitis has been reported in up to a third of PPID horses, even in the absence of hirsutism (Donaldson et al. 2004). The pathogenesis remains elusive. Recent studies have implicated elevated serum insulin concentrations (McGowan et al. 2003, 2013 and Carter et al. 2009) and an equine model of supra-physiological doses of insulin in the face of normal insulin sensitivity and serum glucose concentration resulted in laminitis (Asplin et al. 2007; de Laat et al. 2010). De Laat et al. (2017) showed that the insulin levels in horses with pasture associated laminitis was higher in horses with concurrent PPID and equine metabolic syndrome (EMS), than with either PPID or EMS alone. Interestingly, in this group of horses, the serum insulin concentration was significantly positively correlated with the severity (Obel grade) of laminitis (Obel 1948). Finally, it would be disingenuous to consider laminitis and pathologies of the equine foot while excluding other collagen-type abnormalities occurring concurrently in PPID horses. Alterations in muscle mass, body weight and fat distribution under the influence of POMC-derived peptides or subsequent cortisol or androgen (Morgan et al. 2017) metabolism may fundamentally alter the basement membrane of the equine foot lamellae making it more prone to laminitic episodes. Indeed, a recent paper by Karikoski (2016) showed that horses with PPID had more sharp axial primary epidermal lamellae than control horses and horses with PPID

and concurrent EMS, for reasons that are unknown at this time. These authors also found that the degree of lamellar change was correlated with having PPID and hyperinsulinemia. This suggested that older horses could have concurrent PPID and EMS and that the laminitis associated with PPID may actually be a function of EMS and not PPID per se.

The pathophysiology behind weight loss in PPID horses is unknown. This early clinical sign occurs in up to 88% of horses with PPID, but is sometimes absent. There are even low numbers of horses which have a normal body condition or that are obese (Hillyer et al. 1992; Schott 2002). Fat redistribution, as evidenced by bulging supra-orbital fat pads, a “cresty” neck, tail head fat, as well as pre-mammary and preputial fat (Hillyer et al. 1992) occurs in between 15% and 30% of horses with PPID (McFarlane 2011). Typically, cases present with a pendulous abdomen and loss of epaxial musculature. Interestingly, muscle biopsies of these abnormal horses indicate histological changes consistent with glucocorticoid excess in other species (Tice et al. 1967; Pleasure et al. 1970; Aleman et al. 2006, 2010). The role, if any, of the POMC-derived peptides in PPID-associated muscle atrophy or obesity has not been determined. Given that a significant proportion of PPID horses are now known to have concurrent EMS (30% are hyper-insulinemic; Donaldson et al. 2004; Karikoski et al. 2011; Ireland et al. 2013; Welsh 2016) the complex interrelationship between the disease conditions makes apportioning clinical signs difficult.

Hyperhidrosis is commonly reported as a clinical sign in horses with PPID (Schott 2002). These animals are not typically hyperthermic and thus the sweating may be the result of the

hypertrichosis, in which case simply clipping the excess hair from the horse may result in resolution of this clinical sign. In other cases, compression of the hypothalamic thermal regulation center may account for the abnormality, however, this has not been determined. There are also cases of anhidrosis (lack of sweating) being reported in cases of PPID (McFarlane 2010).

Polyuria and polydypsia has been inconsistently reported in PPID horses, occurring in between 0% (van der Kolk et al. 1993) and 76% of horses (Hillyer et al. 1992). Overall, the incidence is approximately 30% (McFarlane 2011). Mechanisms postulated include reduced antidiuretic hormone secretion from the pars nervosa due to compression from the pars intermedia, an osmotic diuresis due to increased circulating levels of glucose, as well as an unknown effect of increased cortisol concentrations acting in the central nervous system.

Docility, lethargy, and less commonly, decreased responsiveness to painful stimuli have been reported, which have been associated with an increase in the production of β -endorphin in PPID horses (Millington et al. 1988). Opportunistic infections associated with the skin, respiratory tract (including dental related sinusitis), and abscesses have been reported in 35% of horses with PPID as compared to 11% of healthy aged horses (McFarlane 2011). The mechanism of these findings is not fully elucidated, however, the increased concentration of a cocktail of immunosuppressive hormones including ACTH, β -endorphin, α MSH and cortisol associated with this problem makes a simple etiology unlikely. Interestingly, work by McFarlane et al. (2015) showed that neutrophil

function was reduced in PPID horses (decreased oxidative burst activity and adhesion) compared to control horses.

Reproductive problems in aged PPID positive mares are reported to be multiple and include failure to cycle, or inappropriate cyclicity, endometritis, infertility, and inappropriate lactation (Love 1993; McCue 2002). This broad group of abnormalities is typically reported in review papers and the underlying mechanism(s) are unknown (Johnson et al. 2011). One suggestion is that compression of the pars distalis by the pars intermedia leads to a reduction in luteinizing hormone and follicular stimulating hormone secretion and altered cyclicity in PPID positive females (Linse 2011). There is only 1 case report of a mare fitting the clinical and clinicopathological profile of PPID being treated medically and then beginning to cycle normally (Panzani et al. 2003). Beyond this report, the current author can find no direct evidence of the effect of PPID on reproductive function in age and sex matched horses.

1.6 DIAGNOSTIC TESTING

1.6.1 HORMONE CONCENTRATIONS

Definitive diagnosis of equine PPID is complicated as there is no unequivocal test. The disease process is slowly progressive such that by the time a diagnosis is attempted, the pathological changes within the hypophysis have likely been present for a significant period of time. Historically, the majority of clinicians were presented with a hypertrichotic horse which formed

the basis for the diagnosis. Subsequent to that, the evaluation of certain serum hormone concentrations could increase the likelihood of a definitive diagnosis, but there is no definitive antemortem test to which to refer. Recently, however, with the help of industry funding^a, the number of non-hypertrichotic horses being tested for PPID has increased dramatically in the UK, Europe and Australia.

There is a distinct seasonality to the hormonal output of the equine pars intermedia, just as in other seasonal breeders. As such, plasma concentrations of the main POMC-derived peptides, α MSH and ACTH, are significantly elevated between August and October (possibly as early as July), autumn in the Northern Hemisphere (Logan et al. 1980; McFarlane et al. 2004; Donaldson et al. 2005; Beech et al. 2009; Lee et al. 2010; Frank et al. 2010; Place et al. 2010; Copas and Durham 2012). Similarly, Secombe et al. (2017) indicated that there was a day-length effect on endogenous basal ACTH production in the Southern Hemisphere (Australia) and that horses closer to the equator (Townsville, Queensland) had a higher basal level of ACTH with a reduced elevation between the summer solstice and autumn equinox (January to May), than horses further from the equator (Perth, Western Australia) who had a lower basal endogenous concentration but a greater elevation in the January to May period. These researchers suggested that the latitude difference was associated with reduced day length changes closer to the equator. The overall effect is that variations in seasonal endogenous basal ACTH concentrations can result in false-positive diagnoses when diagnostic tests are performed without using seasonally adjusted reference ranges.

There are a variety of hormone-based tests used for the diagnosis of PPID. Historically, the most common was the dexamethasone suppression test (Dybdal et al. 1994) which was originally reported to have 100% sensitivity and 100% specificity. In the normal horse, ACTH from the pars distalis acts on the adrenal gland to release cortisol. An increase in the circulating concentration of cortisol then acts in negative feedback fashion to reduce the output of ACTH. Administration of dexamethasone (a corticosteroid-based hormone) in the normal horse will therefore result in a suppression of the basal cortisol level by reducing the production of ACTH. In the horse with PPID, the increased ACTH production is derived from the pars intermedia, not the pars distalis, and is not responsive to the negative feedback inhibition due to a receptor lack, rather than neoplastic autonomy (Antakly et al. 1984; Seger et al. 1988), and so cortisol suppression does not occur (cortisol greater than 1 µg/dL 19 hours after dexamethasone administration is suggestive of PPID). Additionally there is a concern amongst clients and veterinarians that using a corticosteroid (dexamethasone) will induce laminitis in these compromised animals and thus the dexamethasone suppression test has fallen out of favor.

In horses with PPID, ACTH is produced in the pars intermedia as well as the pars distalis, and so, an increase in the basal level of this circulating hormone was reported as a simple, single test for PPID (Couëttil et al. 1996; Lee et al. 2010). McGowan et al. (2013) reported a sensitivity and specificity of 80% and 83%, respectively, for a single serum ACTH sample using a cut-off value of 29.7 pg/mL in seasons other than autumn. In autumn, using a cut-off value of 77.4 pg/mL the sensitivity improved to 100% with a specificity of 95%. An elevation in the basal plasma concentration of ACTH is currently recommended as a diagnostic test for PPID, on the caveat

that seasonally adjusted reference values (greater than 35 to 50 pg/mL, chemiluminescent or radioimmunoassay respectively; November to July) and greater than 100 pg/mL (August to October) are used (McFarlane 2011; Copas and Durham 2012). Most recently Durham (2017) suggested that these adjusted values may need further investigation as there appeared to be a lower level of endogenous basal ACTH concentration in horses in April, preceding the rise from July to November. Furthermore, it is important to note that there are significant differences in the values returned by different testing methodologies (chemiluminescent, immunofluorescent or radioimmunoassay; Irvine et al. 2016; Knowles et al. 2017), there may also be an age, sex, pony breed (Shetlands) and colour (grey) effect of having higher endogenous basal ACTH levels (Durham 2017).

In contrast, irrespective of disease status, α MSH is produced solely in the pars intermedia. TRH stimulation of normal and PPID horses (McFarlane 2006) indicated that both normal and PPID horses had marked increases in α MSH after TRH stimulation. There was no significant difference in the magnitude of the response, although horses with PPID had higher α MSH levels both before and after stimulation. McGowan et al. (2013) reported using elevations in basal endogenous α MSH levels as a diagnostic test. This had a moderately good specificity and sensitivity of 93% and 59%, respectively, using a cut-off value of 52.0 pmol/L in seasons other than autumn. In autumn the specificity and sensitivity improved to 97% and 100% respectively, using a cut-off value of 165.4 pmol/L. In this paper, the definitive diagnosis was provided using hirsutism, in addition to 3 or more clinical signs of PPID.

The ACTH stimulation test is based upon the supposition that in the face of an increased concentration of circulating ACTH, an abnormally enlarged (or primed) adrenal gland will respond by increasing the output of cortisol to be measured in the serum. Unsurprisingly, as adrenal gland hyperplasia in horses with PPID is uncommon (McFarlane 2011), and ACTH concentration is affected by a multitude of factors (Nagata et al. 1999; Fazio et al. 2008), conflicting results have been reported (Hillyer et al. 1992; Dybdal et al. 1994; van der Kolk et al. 1995).

As described above, melanotrophs of the pars intermedia of the pituitary are stimulated by TRH produced in the hypothalamus. This positive effect is retained in PPID and is the basis behind the TRH-stimulation test, which originally measured the increase in serum cortisol produced as a result of exogenously administered TRH (Beech et al. 1985). However, non-diseased animals also have a response to TRH stimulation, and 10 of 16 animals had greater than 30% increase in serum cortisol (McFarlane et al. 2006). To circumvent this problem, Beech et al. (2007) reported measuring serum concentration of ACTH after TRH stimulation (1 mg intravenously), instead of cortisol, and used cut-off values of 100 pg/mL and 35 pg/mL measured 10 minutes and 30 minutes after TRH injection. This test is currently advocated in cases where an equivocal endogenous basal ACTH concentration has been measured. The current recommendation is that 1 mg of TRH is administered and blood drawn for the determination of ACTH concentration before administration and at 10 and 30 minutes after administration. Cut-off values are reported to be greater than 110 pg/mL at 10 minutes, and greater than 65 pg/mL at 30 minutes after stimulation, however, both Goodale et al. (2013) and Funk et al. (2011), reported that further studies were required to determine cut-off values. A recent Australian paper (Byrne et al. 2017)

reported the high variability of autumnal TRH stimulation test results in normal horses in Australia, noting that there was considerable overlap between PPID and non-PPID affected horses. Adams et al. (2017) evaluated the seasonal effect of ACTH response to TRH stimulation and noted a sensitivity and specificity of 86% and 92%, respectively, in the autumn months, with a cut-off of 480 pg/mL. In the non-autumn months a cut-off of 178 pg/mL led to sensitivities and specificities of 78% and 95%, respectively, in determining PPID. The same researchers showed that evaluating the ACTH concentration at 30 minutes improved their sensitivity and specificity to 90% and 96%, using a cut off of 209 pg/mL in the autumn and a sensitivity and specificity of 87% and 86%, respectively in non-autumn months. In this study, there appeared to be an ability to differentiate between the normal, subclinical (not overtly PPID horse), and clearly hypertrichotic PPID horses. Chapman et al. (2017) reported on using 3 (0.5 mg, 1 mg and 2 mg) and Stallenberger et al. (2017) on 2 (0.5 mg and 1 mg) different amounts of TRH to perform the stimulation test with no significantly different mean plasma ACTH concentrations noted between groups after stimulation in either study.

A combined test (using dexamethasone suppression and TRH stimulation) has been advocated historically (Frank et al. 2006) as increasing the specificity (76%) and sensitivity (88%) of diagnosis above that of either single test alone. The positive and negative predictive values were 71% and 90%, respectively.

Given the effect of exogenous prolactin on hair shedding in the horse, Schott et al. (2017) assessed the use of blood prolactin concentrations for use as a screening test for PPID in the

horse. These researchers found that while prolactin levels were higher in PPID horses, the variability was such that the sensitivity and specificity was only 77% and 54%, respectively, with a cut-off of greater than 3.5 ng/mL. It was, therefore, deemed not to be of use as a screening test.

Horses with PPID have been reported to lose the cortisol circadian rhythm (Dybdal et al. 1994). As such, less than a 30% difference between morning and evening serum cortisol concentrations was considered as a possible diagnostic test (Douglas 1999), however, it ultimately proved unsuitable for several reasons. Firstly, there is a normal loss of circadian rhythm inherent with aging and also with generalized disease. Secondly, even in the absence of disease, the amplitude of the variation over the course of a day is low. Added to this, there are a myriad other factors such as stress, feeding, and exercise that can alter the basal cortisol levels to the point that determining a useful cut-off value between PPID and normal horses has proven difficult (McFarlane 2011; Cordero et al. 2012). Interestingly, a recent study found that tear concentration of cortisol in PPID horses was found to be higher than aged control horses, despite there being no significant difference in serum cortisol concentrations. Additionally, the ratio between tear and serum cortisol concentrations was higher in PPID than in aged controls (Hart et al. 2016). The focus of the paper was on the delayed corneal wound healing in PPID horses. It is possible that this easily obtained sample might be useful as a diagnostic test in the future.

Another possible avenue for PPID diagnosis is proteomics. McFarlane et al. (2017) are developing a diagnostic test based on matrix-assisted laser desorption/ionization (MALDI)-Time of Flight (TOF) Mass Spectrometry. This methodology differs from the previously mentioned tests in that it seeks out plasma peptide signatures and is based upon the premise that in PPID

there are a significant number of altered peptides and POMC derivatives in the circulation that are not present in the normal horse. Thus far, it is in the design and testing phase but may represent the next quantum leap in the early diagnosis of PPID in the horse.

1.6.2 IMAGING

The recent advent of advanced diagnostic imaging modalities has not been used to its full advantage in PPID. Magnetic resonance imaging (MRI) is the chosen modality for soft tissue imaging. There are 2 different types of MRI unit available for use in the horse: a high-field (3 Tesla) machine requiring general anesthesia, the use of which has been reported in the assessment of the pituitary gland of PPID horses (Schott et al. 2015); and a smaller, low field (1 Tesla) unit designed for standing animals. Standing cranial MRI using the smaller, low field units would limit cost and improve availability of technology. However, bore size – the area into which the region of interest must fit – precludes brain imaging in mature horses, which specifically excludes use in PPID patients.

Computed tomography (CT) is a technique that is best used for bone imaging, although good soft tissue delineation is also possible. CT is routinely used for imaging the distal limbs and heads of equine patients under general anesthesia and, more recently, standing CT examination of the equine head has gained popularity in some academic institutions and private practices. The ability to use the latter modality in a standing horse reduces both cost and risk for the equine patient. Imaging of soft tissues can be improved by contrast enhancement as illustrated succinctly in a paper reporting the use of high volume (240 mL) intravenous contrast enhancement to

improve the ability of researchers to delineate areas of damaged cerebrum in a study of neurological horses (Lacombe 2010). CT has been used with and without contrast enhancement to assess the ability to accurately measure the size of normal equine pituitary glands in-vivo (McKlveen et al. 2003) and, most recently, contrast enhanced computed tomography was used to study the effect of long term medical treatment of horses with PPID using pergolide mesylate (Pease et al. 2011). Problems associated with contrast enhancement of the brain tissues using the published methodology were that the high volume of contrast material represented a significant cost. Additionally, the use of intravenous contrast material resulted in volume dilution of the medium throughout the body tissues with proportionately less being distributed in the soft tissues of the brain. Theoretically, by targeting a specific body-part, i.e., delivering the contrast material solely to this region, the volume depletion effect would be reduced, and result in superior image quality and reduced cost. Using specifically-timed contrast-enhanced diagnostic imaging would also allow the arterial supply to the pars intermedia of the pituitary gland to be elucidated. Comparison of the information obtained from normal horses with that obtained from horses with PPID may allow interventional cerebrovascular surgery to be performed in PPID patients (see Chapter 6).

1.6.3 NECROPSY

Necropsy and histological examination of the pituitary gland long-represented the definitive diagnostic test for PPID. However, the hypophysis undergoes age-related morphological change in both the pars intermedia and the pars distalis (Leitenbacher and Herbach 2016), complicating the definitive diagnosis of PPID. The hypophysis is typically 2 to 5 times larger in horses with PPID than in unaffected horses, which is due to a combination of hypertrophy and hyperplasia of the cells of the pars intermedia. These melanotrophs are present in nodules or follicular structures separated by fine connective tissue (Boujon et al. 1993; van der Kolk et al. 2004; Glover et al. 2007; Miller et al. 2008). Given that there is considerable overlap in the size, weight and density of PPID and normal hypophyses, a histological grading system was developed (van der Kolk et al. 2004). In this system, histologic lesions of the pars intermedia, pars distalis, or both, were determined to be 0 if there were no lesions; 1, if there were single or multiple cysts; 2, if there was focal or multifocal hyperplasia; 3, if there was a single or multiple microadenomas (arbitrarily classified as being less than 5 mm in size); and 4, if there was a macroadenoma (greater than 5 mm in size). McFarlane et al. (2005) subsequently reported that histological grade only correlated with antemortem diagnostic test results 79% of the time. Miller et al. (2008) were the first to develop a 1 to 5 graded scoring system and reported that only adenomas graded as 3 or higher were associated with elevations in plasma ACTH levels after stimulation with a D2R antagonist (domperidone), and it may simply be that the diagnostic tests are not sensitive enough to detect the hormonal changes and that the systemic response to the elevations in POMC-derived peptides may have yet to reach the lower-limit of response. More recently, a

modification of this system was reported by Leitenbacher and Herbach (2016) where grade 1 represented a normal pituitary gland. Increasing grades represented gradual increases in abnormality such that grade 2 was assigned to focal or multifocal enlargement of the pars intermedia, grade 3 was diffuse enlargement of the pars intermedia, grade 4 represented diffuse enlargement of the pars intermedia with microadenomas (less than 5 mm in diameter) and grade 5 was diffuse enlargement with macroadenomas (greater than 5 mm). Despite the age-related changes to the equine hypophysis, the authors reported that a definitive diagnosis of PPID could be made using a combination of pituitary weight and quantitative stereological change, specifically the volume of the pituitary gland and the volume of the pars intermedia. Pars intermedia adenomata were also classified as non-functional (or age-associated) or PPID-associated adenomas, depending on the evidence of clinical signs of PPID. The latter classification is controversial as there is no evidence to suggest that microadenomata are non-functional.

1.7 TREATMENT

1.7.1 MEDICAL

PPID results in a disease syndrome of the older horse and as such a holistic approach to management must be taken. The provision of sufficient shelter, water, appropriate diet and general husbandry, such as the routine maintenance of both oral health and podiatry, are important.

The drug of choice is pergolide mesylate, an ergot-derived D2R agonist which down regulates POMC-derived peptide production via a G-protein coupled mechanism. This drug needs to be given for the life term of the horse. Efficacy of this drug has been well documented (Munoz et al. 1996; Schott et al. 2001; Donaldson et al. 2002; Perkins et al. 2002; Sgobini et al. 2004). It was initially used for the treatment of human Parkinson's disease, but removed from the market due to its association with valvular endocarditis. An exemption was made for compounded products to be used for equine PPID, however, the efficacies varied due to instabilities in aqueous carriers and the compounded product had to be stored in the refrigerator (Davis et al. 2009). Recently, a new equine pergolide product has been approved by the Federal Drug Administration in the USA and Health Canada in Canada, and is also being used in Europe (Prascend, Boehringer Ingleheim). Treatment is usually initiated as 1 mg per horse and the dose is titrated up, in 0.5 mg or 1 mg increments, until clinical and clinicopathological features of the disease are normalized. Therapeutic monitoring can be performed, however, these hormone-response tests may take several months to normalize (McFarlane et al. 2017). Why these responses take such a long time to normalize is difficult to understand when pharmacokinetics and pharmacodynamics of oral pergolide mesylate showed that the pergolide concentration reached a steady state within 3 days of the initiating treatment. There was a concurrent significant reduction in the plasma ACTH concentration and the authors of this study (Rendle et al. 2017) suggested that earlier follow-up testing may be possible. There is also a suggestion (McFarlane 2011) that individual requirements may increase over time, as occurred in human Parkinson's patients and there may also be a season effect, with additional pergolide being needed to control ACTH concentrations in PPID horses in the summer and fall (McFarlane et al. 2017).

Two other drugs have been used in the management of PPID. Cyproheptadine, a serotonin antagonist with an antihistamine and an antimuscarinic effects has been used, however, in studies comparing the efficacy of either cyproheptadine or pergolide in normalizing the clinical signs associated with PPID, there was either no difference between the drugs (Perkins et al. 2002) or a superiority of pergolide (Donaldson et al. 2002). Cyproheptadine has been used in combination with pergolide in refractory cases of PPID (Donaldson et al. 2002; Perkins et al. 2002). Trilostane has been reported to improve the clinical signs (primarily laminitis, PU / PD and lethargy) associated with PPID, but not the dexamethasone suppression test results (McGowan et al. 2003). It is a competitive inhibitor of 3 β -hydroxysteroid dehydrogenase, the enzyme responsible for production of cortisol from cholesterol. As such, this drug may improve the clinical signs of PPID in the small percentage of horses with adrenal gland hyperplasia, but has no effect on pituitary derived hormones.

1.7.2 SURGICAL

Surgical intervention in the treatment of human brain tumors is common. These procedures can be performed via a craniotomy; “key-hole” approaches using stereotaxic guidance; cerebrovascular neurosurgery (blocking specific arteries to tumors to cause hypoxic necrosis); neuroendoscopically; or specifically in some cases of tumors of the pituitary gland, via a trans-nasal approach (Krisht 2002; Cappabianca 2004). Pituitary tumors in cats and dogs have also been removed (Meij 1997) using a trans-oral approach with relapse-free rates in dogs being reported as 92% (Meij et al. 1998) and 91% at 1 year and 80% at 2 years (Meij et al. 2002). Initial reports of surgery in canine pituitary-dependent Cushing’s disease were exciting in that

they reported that residual cells left within the sella turcica hypertrophied resulting in a lack of need for post-surgical hormone therapy (Meij et al. 1997). Unfortunately, later publications indicated that this was likely a result of incomplete removal of the initial adenoma (Meij et al. 2002).

Brain surgery is rarely performed in the horse. There are single case reports of the drainage of a brain abscess after localization using CT (Allen et al. 1987; Cornelisse et al. 2001; Janicek et al. 2006) and a CT-guided biopsy of an intra-cerebral mass which was subsequently diagnosed as a cholesterinic granuloma (Vanschandevijl et al. 2008). Kramer et al. (2007) reported on 3 approaches to the equine cranium (rostromental, suboccipital and the transfrontal) in cadaver heads, which gave limited access to the rostral, dorsal and caudal aspects of the cerebral cortex and cerebellum. No described approach gave access to the hypophysis. There is a single case report of an open craniotomy and severing of the hypothalamic-pituitary axis using a laser (Locatelli 1984), which unfortunately does not describe the technique or outcome sufficiently well to allow repetition. It is important to note that any surgical intervention in the PPID horse must represent an improvement on current medical treatment modalities. Namely, there should be no need for daily medication beyond the immediate post-surgical phase. Essentially, this means that abnormal melanotrophs from the pars intermedia need to be excised en-bloc, or otherwise disabled, without damage to the other important regions of the gland. This may seem a difficult task, given that the pars intermedia is interposed between the pars distalis and the pars nervosa; however, in end-stage (Grade 5) pituitary glands the pars distalis is often reduced to a thin strip of tissue on the outside of the grossly enlarged gland, meaning that the potential for damage may be lessened.

Potential surgical approaches to the hypophysis include myeloscopy via a foramen magnum access point; a trans-sphenopalatine sinus approach; a ventral craniotomy (using a Viborg's triangle or trans-laryngeal approach) via a slot-ostotomy of the basisphenoid bone; or possibly, cerebrovascularly. The orientation of the equine brain relative to the long axis of the head is approximately parallel, as with most quadrupeds. However, it is the anatomical arrangement of the paranasal sinuses in this species that imparts a critical difference to any potential surgical approach to the sella turcica. In addition to this, as the pars intermedia enlarges there may also be an as yet unreported alteration in the orientation (size and shape) of the gland, which would have major implications on any surgical intervention or invasive treatment.

As noted above, Vitums (1975) specifically did not examine the arterial anatomy of the pars intermedia of the equine pituitary gland. If the arterial vascularization of the pars intermedia can be substantiated it may be that, with contrast enhancement, the neovascularization associated with adenomatous expansion in PPID can be visualized and subsequently occluded via fluoroscopy, CT or MRI-guided coils. This approach may be the least invasive and most elegant treatment. Another option may be to use the venous access as described by Vitums (1978) and exploited by Irvine et al. (1984). If catheterization of the ventral cavernous sinus for blood sample collection is possible, then access to the pituitary gland for treatment purposes, as described by Sakes et al. (2015), is a realistic and exciting minimally invasive approach.

Despite the fact that PPID was first reported 85 years ago, only recently have some pathophysiological mechanisms been described. Similarly, there is only 1 common treatment, which was first described 30 years ago. A further understanding of the pathophysiology of

disease, an early, definitive diagnostic test and a less onerous treatment for this chronic condition is needed.

1.8 GENERAL OBJECTIVES AND SPECIFIC AIMS

The long term goal of this research is to explore the feasibility of developing a targeted tissue-specific approach for the treatment of equine PPID. This thesis constitutes a first approach to this goal. The specific aims of this thesis are:

1. To confirm the need for this advanced therapy by determining the prevalence of PPID in horses globally (Chapter 2).
2. To continue the investigation of the underlying cellular mechanism of PPID by sequencing the POMC, PC1 and PC2 genes, identifying a suitable internal control gene for use in the equine pituitary gland, examining gene expression of pro-hormone convertases, and quantifying the differences in POMC, ACTH, α MSH and CLIP hormone concentrations in affected and unaffected horses (Chapter 3).
3. To investigate the methodology for site-specific application of future therapy for equine PPID (Chapters 4, 5, and 6).

FOOTNOTES

^a <https://www.talkaboutlaminitis.co.uk/>

1.9 REFERENCES

Adams A, Siard MH, Reedy SE et al. Evaluating seasonal influences on hormone responses to a diagnostic test (thyrotropin-releasing hormone stimulation) advocated for early diagnosis of pituitary pars intermedia dysfunction (PPID). In: Proc Int Eq Endocrinol Summit (Havemeyer Foundation). 2017; 12.

Aleman M, Nieto JE. Gene expression of proteolytic systems and growth regulators of skeletal muscle in horses with myopathy associated with pituitary pars intermedia dysfunction. Am J Vet Res 2010; 71: 664-670.

Aleman M, Watson JL, Williams DC et al. Myopathy in horses with pituitary pars intermedia dysfunction (Cushing's disease). Neuromuscl Disord 2006; 16: 737-744.

Alexander SL, Irvine CHG, Donald RA. Dynamics of the regulation of the hypothalamo-pituitary-adrenal (HPA) axis determined using a nonsurgical method of collecting pituitary venous blood from horses. Front Neuroendocrinol 1996; 17: 1-50.

Allen JR, Barbee DD, Boulton CR et al. Brain abscess in a horse: Diagnosis by computed tomography and successful surgical treatment. J Am Vet Med Assoc 1987; 19: 552-555.

Antakly T, Eisen H. Immunocytochemical localization of glucocorticoid receptor in target cells. *J Endocrinol* 1984; 115: 1984-1989.

Asplin KE, Sillence MN, Pollitt CC et al. Induction of laminitis by prolonged hyperinsulinaemia in clinically normal ponies. *Vet J* 2007; 174: 530-535.

Banse H, McFarlane D. Comparison of seasonal TRH stimulation test results in horses with PPID. In: *Proc Int Eq Endocrinol Summit (Havemeyer Foundation)*. 2017; 16-17.

Beech J, Garcia M. Hormonal response to thyrotropin-releasing hormone in healthy horses and in horses with pituitary adenoma. *Am J Vet Res* 1985; 46: 1941-1943.

Beech J, Boston R, Lindborg S et al. Adrenocorticotropin concentration following administration of thyrotropin-releasing hormone in healthy horses and those with pituitary pars intermedia dysfunction and pituitary gland hyperplasia. *J Am Vet Med Assoc* 2007; 231: 417-426.

Beech J, Boston RC, McFarlane D et al. Evaluation of plasma ACTH, α -melanocyte-stimulating hormone, and insulin concentrations during various photoperiods in clinically normal horses and ponies and those with pituitary pars intermedia dysfunction. *J Am Vet Med Assoc* 2009; 235: 715-722.

Beech J, McFarlane D, Lindborg S et al. α -Melanocyte-stimulating hormone and adrenocorticotropin concentrations in response to thyrotropin-releasing hormone and comparison with adrenocorticotropin concentration after domperidone administration in healthy horses and horses with pituitary pars intermedia dysfunction. *J Am Vet Med Assoc* 2011; 238: 1305-1315.

Boujon CE, Bestetti GE, Meier HP et al. Equine pituitary adenoma: a functional and morphological study. *J Comp Pathol* 1993; 109: 163-178.

Brosnahan MM and Paradis MR. Demographic and clinical characteristics of geriatric horses: 467 cases (1989-1999). *J Am Vet Med Assoc* 2003a; 223: 93-98.

Brosnahan MM and Paradis MR. Assessment of clinical characteristics, management practices, and activities of geriatric horses. *J Am Vet Med Assoc* 2003b; 223: 99-103.

Byrne DP, Secombe CJ, Tan RHH et al. Highly variable autumnal TRH-stimulation tests in normal horses at two Australian locations. In: *Proc Int Eq Endocrinol Summit (Havemeyer Foundation)*. 2017; 13.

Cappabianca P, Cavallo LM, de Divitiis E. Endoscopic endonasal transsphenoidal surgery. *Neurosurg* 2004; 55: 933-941.

Chandler KJ, Mellor DJ. A pilot study of the prevalence of disease within a geriatric horse population. In: *Proc Congr Brit Equine Vet Assoc* 2011; 217.

Chapman AM, Ainsworth S, Keowan M et al. Adrenocorticotrophin hormone response to varying dosages of thyrotropin releasing hormone in normal horses. In: Proc Int Eq Endocrinol Summit (Havemeyer Foundation). 2017; 11.

Copas VEN, Durham A. Circannual variation in plasma adrenocorticotrophic hormone concentrations in the UK in normal horses and ponies, and those with pituitary pars intermedia dysfunction. Equine Vet J 2012; 44: 440-443.

Cordero M, Brorsen BW, McFarlane D. Circadian and circannual rhythms of cortisol, ACTH, and α -melanocyte-stimulating hormone in healthy horses. Domest Anim Endocrinol 2012; 43: 317-324.

Cornelisse CJ, Schott HC, Lowrie CT et al. Successful treatment of intracranial abscesses in 2 horses. J Vet Intern Med 2001; 15: 494-500.

Couëtill L, Paradis MR, Knoll J. Plasma adrenocorticotropin concentration in healthy horses and horses with clinical signs of hyperadrenocorticism. J Vet Intern Med 1996; 10: 1-6.

Davis JL, Kirk LM, Davidson GS et al. Effects of compounding and storage conditions on stability of pergolide mesylate. J Am Vet Med Assoc 2009; 234: 385-399.

Donaldson MT, Jorgensen AJR, Beech J. Evaluation of suspected pituitary pars intermedia dysfunction in horses with laminitis. J Am Vet Med Assoc 2004; 224: 1123-1127.

Donaldson MT, LaMonte BH, Morresey P et al. Treatment with pergolide or cyproheptadine of pituitary pars intermedia dysfunction (equine Cushing's disease). *J Vet Intern Med* 2002; 16: 742-746.

Donaldson MT, McDonnell SM, Schanbacher BJ et al. Variations in plasma adrenocorticotrophic hormone concentration and dexamethasone suppression test results with season, age and sex in healthy ponies and horses. *J Vet Intern Med* 2005; 19: 217-222.

Douglas R. Circadian cortisol rhythmicity and equine cushing's-like disease. *J Eq Vet Sci* 1999; 19: 684, 750-753.

Dowling PM, Williams MA and Clark TP. Adrenal insufficiency associated with long-term anabolic steroid administration in a horse. *J Am Vet Med Assoc* 1993; 203: 1166-1169.

Durham A. Is equine pars intermedia activity subdued in the spring ? In: *Proc Int Eq Endocrinol Summit (Havemeyer Foundation)*. 2017; 4-5.

Durham A. Horse-factors influencing the seasonal increase in plasma ACTH secretion. In: *Proc Int Eq Endocrinol Summit (Havemeyer Foundation)*. 2017; 36.

Dybdal N, Hargreaves KM, Madigan JE et al. Diagnostic testing for pituitary pars intermedia dysfunction in horses. *J Am Vet Med Assoc* 1994; 204: 627-632.

Engler D, Pham T, Liu JP et al. Studies of the regulation of the hypothalamic-pituitary- adrenal axis in sheep with hypothalamic-pituitary disconnection. II. Evidence for in vivo ultradian hypersecretion of proopiomelanocortin peptides by the isolated anterior and intermediate pituitary. *J Endocrinol* 1990; 127: 1956-1966.

Evans DR. The recognition and diagnosis of a pituitary tumor in the horse. In: *Proc Am Assoc Eq Pract.* 1972; 18: 417-419.

Fazio E, Medica P, Aronica V et al. Circulating beta-endorphin, adrenocorticotrophic hormone and cortisol levels of stallions before and after short road transport: stress effect of different distances. *Acta Vet Scand* 2008; 50: Special Suppl 1-7.

Frank N, Andrews FM, Sommardahl CS et al. Evaluation of the combined dexamethasone suppression / thyrotropin -releasing hormone stimulation test for the detection of pars intermedia pituitary adenomas in horses. *J Vet Intern Med* 2006; 20: 987-993.

Frank N, Elliott SB, Chameroy F et al. Association of season and pasture grazing with blood hormone and metabolite concentrations in horses with presumed pituitary pars intermedia dysfunction. *J Vet Intern Med* 2010; 24: 1167-1175.

Funk RA, Stewart AJ, Wooldridge AA et al. Adrenocorticotrophic Hormone and α -Melanocyte-Stimulating Hormone in Response to Thyrotropin-Releasing Hormone in Normal, Aged Horses. *J Vet Intern Med* 2011; 25: 579-585.

Gehlert DR, Bishop JF, Schafer MP et al. Rat intermediate lobe in culture: dopaminergic regulation of POMC biosynthesis and cell proliferation. *Peptides* 1988; 9(Suppl 1): 161-168.

Glover CM, Miller LM, Dybdal NO et al. Extrapituitary and pituitary pathological findings in horses with pituitary pars intermedia dysfunction: a retrospective study. *J Equine Vet Sci* 2009; 29: 146-153.

Goodale L, Hermida P, Oench SD et al. Assessment of compounded thyrotropin releasing hormone for the diagnosis of pituitary pars intermedia dysfunction in horses. *J Vet Intern Med* 2013; 27: 656-656.

Goudreau JL, Lindley SE, Lookingland KJ et al. Evidence that hypothalamic periventricular dopamine neurons innervate the intermediate lobe of the rat pituitary. *J Neuroendocrinol* 1992; 56: 100-105.

Hall JE. Pituitary hormones and their control by the hypothalamus. In: Guyton and Hall eds. *Textbook of Medical Physiology* 12th Edn. Philadelphia, Saunders Elsevier. 2011; 895.

Hart KA, Kitchings KM, Kimura S et al. Measurement of cortisol concentration in the tears of horses and ponies with pituitary pars intermedia dysfunction. *Am J Vet Res* 2016; 77: 1236-1244.

Hillyer MH, Taylor FGR, Mair TS. Diagnosis of hyperadrenocorticism in the horse. *Equine Vet Educ* 1992; 4: 131-134.

Hurcombe SDA. Hypothalamic-pituitary gland axis function and dysfunction in horses. *Vet Clin North Am Equine Pract.* 2011; 27: 1-17.

Innera M, Petersen AD, Desjardin DR et al. Comparison of hair follicle histology between horses with pituitary pars intermedia dysfunction and excessive hair growth and normal aged horses. *Vet Dermatol* 2013; 24: 212-217.

Ireland JL, Clegg PD, McGowan CM et al. A cross-sectional study of geriatric horses in the United Kingdom. Part 2: Health care and disease. *Equine Vet J* 2011; 43: 37-44.

Ireland JL, Wylie CE, Collins SN et al. Preventive health care and owner-reported disease prevalence of horses and ponies in Great Britain. *Res Vet Sci* 2013; 95: 418-424.

Irvine CH, Hunn R. Long term collection of pituitary venous blood in the unrestrained horse. *NZ Med J* 1984; 97: 735.

Irvine CHG, Alexander SL. A novel technique for measuring hypothalamic and pituitary hormone secretion rates from collection of pituitary venous effluent in the normal horse. *J Endocrinol* 1987; 113: 183-192.

Irvine KL, Burt K, Hill AJ et al. Initial analytic quality assessment and method comparison of an immunoassay for adrenocorticotrophic hormone measurement in equine samples. *Vet Clin Path* 2016; 45: 154-163.

Janicek JC, Kramer J, Coates JR et al. Intracranial abscess caused by *Rhodococcus equi* infection in a foal. *J Am Vet Med Assoc.* 2006; 228: 251-253.

Johnson PJ, Messer NT, Ganjam VK. Pituitary pars intermedia dysfunction (equine cushing's syndrome). In: *Equine reproduction 2nd edn.* McKinnon AO, Squires L, Vaala WE, Varner DD Eds. Ames, Iowa. Wiley-Blackwell 2011; 2790-2795.

Karikoski NP, Horn I, McGowan TW et al. The prevalence of endocrinopathic laminitis among horses presented for laminitis at a first-opinion/referral equine hospital. *Domest Anim Endocrinol* 2011; 41: 111-117.

Karikoski NP, Patterson-Kane JC, Singer ER et al. Lamellar pathology in horses with pituitary pars intermedia dysfunction. *Equine Vet J* 2016; 48: 472-478.

Knowles EJ, Moreton-Clack MC, Shaw S et al. Comparison of plasma ACTH assays in ponies suggests seasonally dependent assay cross-reactivity. In: *Proc Int Eq Endocrinol Summit (Havemeyer Foundation).* 2017; 6-7.

Korbonits M, Morris DG, Nanzer A et al. Role of regulatory factors in pituitary tumor formation. *Frontiers of Hormone Research; Molecular pathology of the pituitary* 2004; 32: 63-95.

Kobayashi N, Machida T, Takahashi T et al. Elevation by oxidative stress and aging of hypothalamic-pituitary-adrenal activity in rats and its prevention by vitamin E. *J Clin Biochem Nutr* 2009; 45: 207-213.

Kramer J, Coates J, Hoffman AG et al. Preliminary anatomic investigation of three approaches to the equine cranium and brain for limited craniectomy procedures. *Vet Surg* 2007; 36: 500-508.

Krisht AF. The trans-sphenoid approach and its variants. *Contemp Neurosurg* 2002; 24: 654-660.

de Laat MA, McGowan CM, Sillence MN et al. Equine laminitis: induced by 48h hyperinsulinaemia in Standardbred horses. *Equine Vet J* 2010; 42: 129-135.

de Laat MA, Reiche D, Sillence MN et al. Aspects of veterinary-diagnosed endocrinopathic and pasture-associated laminitis : A prospective, cohort study. In: *Proc Int Eq Endocrinol Summit (Havemeyer Foundation)*. 2017; 27.

Lacombe VA, Sogaro-Robinson C, Reed SM. Diagnostic utility of computed tomography imaging in equine intracranial conditions. *Equine Vet J* 2010; 42: 393-399.

Lee Z-Y, Zylstra R, Haritou SJ. The use of adrenocorticotrophic hormone as a potential biomarker of pituitary pars intermedia dysfunction in horses. *Vet J* 2010; 185: 58-61.

Leitenbacher J, Herbach N. Age-related qualitative histological and quantitative stereological changes in the equine pituitary. *J Comp Path* 2016; 154: 215-224.

Linse VJ. Adrenal steroids. In: *Equine reproduction 2nd edn.* McKinnon AO, Squires L, Vaala WE, Varner DD Eds. Ames, Iowa. Wiley-Blackwell 2011; 1665-1668.

Locatelli A. Destruction in-situ of the horse pituitary-gland by laser ray. *Bulletin de l'Académie vétérinaire de France.* 1984; 57: 171-176.

Logan A, Weatherhead B. Photoperiodic dependence of seasonal changes in pituitary content of melanocyte-stimulating hormone. *Neuroendocrinol* 1980; 30: 309-312.

Love S. Equine Cushing's disease. *Br Vet J* 1993; 149: 139-153.

Masson-Pevet M, Gauer F. Seasonality and melatonin receptors in the pars tuberalis in some long day breeders. *Biological Signals* 1994; 3: 63-70.

McCue PM. Equine Cushing's disease. *Vet Clin Equine* 2002; 18: 533-543.

McFarlane D. Advantages and limitations of the equine disease, pituitary pars intermedia dysfunction as a model of spontaneous dopaminergic neurodegenerative disease. *Ageing Res Rev* 2007; 54-63.

McFarlane D. Equine pituitary pars intermedia dysfunction. *Vet Clin Equine* 2011; 27: 93-113.

McFarlane D, Toribio RE. Pituitary pars intermedia dysfunction (Equine Cushing's disease). In: Reed SM, Bayly WM, Sellon DC eds. *Equine internal medicine* 3rd Edn. Philadelphia, Saunders Elsevier. 2010; 1262-1270.

McFarlane D, Beech J, Cribb A. Alpha-melanocyte stimulating hormone release in response to thyrotropin releasing hormone in healthy horses, horses with pituitary pars intermedia dysfunction and equine pars intermedia explants. *Domest Anim Endocrinol* 2006; 30: 276-288.

McFarlane D, Miller LM, Craig LE et al. Agreement in histological assessments of the pituitary pars intermedia in aged horses. *Am J Vet Res* 2005; 66: 2055-2059.

McFarlane D, Donaldson MT, McDonnell SM et al. Effects of season and sample handling on measurement of plasma alpha-melanocyte-stimulating hormone concentrations in horses and ponies. *Am J Vet Res* 2004; 65: 1463-1468.

McFarlane D, Dybdal N, Donaldson MT et al. Nitration and increased alphasynuclein expression associated with dopaminergic neurodegeneration in equine pituitary pars intermedia dysfunction. *J Neuroendocrinol* 2005; 17: 73-80.

McFarlane D, Paradis MR, Zimmel D et al. The effect of latitude of residence, breed and pituitary dysfunction on seasonal plasma ACTH and MSH concentration. *J Vet Intern Med* 2010; 24: 689.

McFarlane D, Hill K, Anton J. Neutrophil function in healthy aged horses and horses with pituitary dysfunction. *Vet Immun. Immunopath* 2015; 165: 99-106.

McFarlane D, Ramachandran A. Development and application of a novel diagnostic test for PPID using MALDI-TOF proteomics. In: *Proc Int Eq Endocrinol Summit (Havemeyer Foundation)*. 2017; 9.

McGowan CM, Neiger R. Efficacy of trilostane for the treatment of equine Cushing's syndrome. *Equine Vet J* 2003; 35: 414-418.

McGowan TW. Aged horse health, management and welfare [doctoral thesis]. St. Lucia, Australia: University of Queensland; 2008.

McGowan TW, Pinchbeck GP and McGowan CM. Evaluation of basal plasma α -melanocyte-stimulating hormone and adrenocorticotrophic hormone concentrations for the diagnosis of pituitary pars intermedia dysfunction from a population of aged horses. *Equine Vet J* 2013; 45: 66-73.

McGowan TW, Pinchbeck GP and McGowan CM. Prevalence, risk factors and clinical signs predictive of pituitary pars intermedia dysfunction in aged horses. *Equine Vet J* 2013; 45: 74-79.

McKlveen TL, Jones JC, Sponenburg DP et al. Assessment of the accuracy of computed tomography for measurement of normal equine pituitary glands. *Am J Vet Res* 2003; 64: 1387-1394.

Meij BP, Mol JA, Bevers MM et al. Residual pituitary function after transsphenoidal hypophysectomy in dogs with pituitary-dependent hyperadrenocorticism. *J Endocrinol* 1997; 155: 531-539.

Meij B, Voorhout G, Rijnberk A. Progress in transsphenoidal hypophysectomy for treatment of pituitary-dependent hyperadrenocorticism in dogs and cats. *Mol. Cellul. Endocrinol.* 2002; 197: 89-96.

Meij BP, Voorhout G, van den Ingh T et al. Transsphenoidal hypophysectomy in Beagle dogs: Evaluation of a microsurgical technique. *Vet Surg* 1997; 26: 295-309.

Meij BP, Voorhout G, van den Ingh T et al. Results of transphenoidal hypophysectomy in 52 dogs with pituitary-dependent hyperadrenocorticism. *Vet Surg* 1998; 27: 246-261.

Mellor DJ, Reid SWJ, Love S et al. Sentinel practice-based survey of the management and health of horses in northern Britain. *Vet Rec* 2001; 149: 417-423.

Miller MA, Pardo ID, Jackson LP et al. Correlation of pituitary histomorphometry with adrenocorticotrophic hormone response to domperidone administration in the diagnosis of equine pituitary pars intermedia dysfunction. *Vet Pathol* 2008; 45: 26-38.

Millington WR, Dybdal NO, Dawson R et al. Equine Cushing's disease: differential regulation of beta-endorphin processing in tumors of the intermediate pituitary. *J Endocrinol* 1988; 123: 1598-1604.

Mitsui I, Jackson LP, Couëtill LL et al. Hypertrichosis in a horse with alimentary T-cell lymphoma and pituitary involvement. *J Vet Diagn Invest* 2007; 19: 128-132.

Morgan RA, Hadoke PWF, Walker BR et al. Androgen excretion in horses with equine metabolic syndrome and pituitary pars intermedia dysfunction. In: *Proc Int Eq Endocrinol Summit (Havemeyer Foundation)*. 2017; 31.

Munoz MC, Doreste F, Ferrer O et al. Pergolide treatment for Cushing's syndrome in a horse. *Vet Rec* 1996; 139: 41-43.

Nagata S, Takeda F, Kurosawa M et al. Plasma adrenocorticotropin, cortisol and catecholamines response to various exercises. *Equine Vet J Suppl* 1999; 30: 570-574.

Obel N. Studies on the histopathology of acute laminitis. Almquist & Wiksells AB. Uppsala, Sweden. 1948

Orth DN, Holscher MA, Wilson MG et al. Equine Cushing's disease: plasma immunoreactive proopiomelanocortin peptide and cortisol levels basally and in response to diagnostic tests. *Endocrinol* 1982; 110: 1430-1441.

Pallaske G. Zur Kasuistik Seltener Geschwülste bei den Haustieren. *Zeitschrift für Krebsforschung* 1932; 36: 342-353.

Panzani D, Vannozzi I, Sgorbini M et al. Embryo recovery rate in a mare affected by Cushing's syndrome. *Vet Res Commun* 2003; 27(Suppl 1): 619-621.

Pease AP, Schott HC, Howey EB et al. Computed tomographic findings in the pituitary gland and brain of horses with pituitary pars intermedia dysfunction. *J Vet Intern Med* 2011; 25: 1144-1151.

Peel AJ, Bouts T, Flach E et al. Pituitary pars intermedia dysfunction (equine Cushing's Disease) in an onager (*Equus hemionus onager*). *J Zoo Wildlife Med* 2009; 40: 773-780.

Perkins GA, Lamb S, Erb HN et al. Plasma adrenocorticotropin (ACTH) concentrations and clinical response in horses treated for equine Cushing's disease with cyproheptadine or pergolide. *Equine Vet J* 2002; 34: 679-685.

Place NJ, McGowan CM, Lamb SV et al. Seasonal variation in serum concentrations of selected metabolic hormones in horses. *J Vet Intern Med* 2010; 24: 650-654.

Pleasure DR, Walsh GO, Engel WK. Atrophy of skeletal muscle in patients with Cushing's syndrome. *Arch Neurol* 1970; 22: 118-125.

Rendle DI, Doran G, Ireland J et al. Pharmacokinetics and pharmacodynamics of oral pergolide mesylate in horses with pituitary pars intermedia dysfunction. In: *Proc Int Eq Endocrinol Summit (Havemeyer Foundation)*. 2017; 38.

Revel FG, Masson-Pévet M, Pévet M et al. Melatonin controls seasonal breeding by a network of hypothalamic targets. *J Neuroendocrinol* 2009; 90: 1-14.

Rohrbach BW, Stafford JR, Clermont RSW et al. Diagnostic frequency, response to therapy, and long-term prognosis among horses and ponies with pituitary pars intermedia dysfunction, 1993-2004. *J Vet Intern Med* 2012; 26: 1027-1034.

Saiardi A, Bozzi Y, Baik JH et al. Antiproliferative role of dopamine: loss of D2 receptors causes hormonal dysfunction and pituitary hyperplasia. *Neuron* 1997; 19:115-126.

Saiardi A, Borrelli E. Absence of dopaminergic control on melanotrophs leads to Cushing's-like syndrome in mice. *Mol Endocrinol* 1998; 12: 1133-1139.

Sakes A, Arkenbout EA, Jelinek F et al. Design of an endovascular morcellator for the surgical treatment of equine Cushing's disease. *Vet Q* 2015; 35: 165-169.

Saland LC. The mammalian pituitary intermediate lobe: An update on innervation and regulation. *Brain Res Bull* 2001; 54: 587-593.

Secombe CJ, Tan RHH, Perara DI et al. The effect of geographical location on circannual adrenocorticotrophic hormone plasma concentrations in Australian horses. In: *Proc Int Eq Endocrinol Summit (Havemeyer Foundation)*. 2017; 3.

Schott HC. Pituitary pars intermedia dysfunction: Equine Cushing's disease. *Vet Clin Equine* 2002; 18: 237-270.

Schott HC, Coursen CL, Eberhart SW et al. The Michigan Cushing's project. *Proc Am Assoc Eq Pract* 2001; 47: 22-24.

Schott HC, Pease AP, Patterson JS et al. Magnetic Resonance Imaging of the Pituitary Gland of Horses With Pituitary Pars Intermedia Dysfunction. In: *Proc Am Assoc Eq Pract* 2015; 61: 530-531.

Schott HC, Marteniuk JV, Miller R et al. Reliability of a clinical scoring system for PPID. In: Proc Int Eq Endocrinol Summit (Havemeyer Foundation). 2017; 15.

Schott HC, Norby B, Thompson DL. Assessment of prolactin concentration as a screening test for PPID. In: Proc Int Eq Endocrinol Summit (Havemeyer Foundation). 2017; 8.

Seger M, van Eekelen J, Kiss J et al. Stimulation of pro-opiomelanocortin gene expression by glucocorticoids in the denervated rat intermediate pituitary gland. J Neuroendocrinol 1988; 47: 350-357.

Sgorbini M, Panzani D, Maccheroni M et al. Equine Cushing-like syndrome: diagnosis and therapy in two cases. Vet Res Commun 2004; 28(Suppl 1): 377-380.

Sojka JE, Jackson LP, Moore G et al. Domperidone causes an increase in endogenous ACTH concentration in horses with pituitary pars intermedia dysfunction (equine Cushing's disease). In: Proc Am Assoc Eq Pract 2006; 52: 320-323.

Stallenberger L, Failing K, Fey K. ACTH responses after application of two TRH doses in healthy horses. In: Proc Int Eq Endocrinol Summit (Havemeyer Foundation). 2017; 14.

Thompson DL, Hoffman R, DePew CL. Prolactin administration to seasonally anestrous mares: reproductive, metabolic, and hair-shedding responses. J Anim Sci. 1997; 75: 1087-1091.

Thompson DL, HoffmanR, DePew CL. Prolactin administration to seasonally anestrous mares: reproductive, metabolic, and hair-shedding responses. *J Anim Sci.* 1997; 75: 1092-1099.

Tice LW, Engel AG. The effects of glucocorticoids on red and white muscles in the rat. *Am J Pathol* 1967; 50: 311-333.

van der Kolk JH, Heinrichs M, van Amerongen JD et al. Evaluation of pituitary gland anatomy and histopathologic findings in clinically normal horses and horses and ponies with pituitary pars intermedia adenoma. *Am J Vet Res* 2004; 65: 1701-1707.

van der Kolk JH, Ijzer J, Overgaauw PA et al. Pituitary independent Cushing's syndrome in a horse. *Equine Vet J* 2001; 33: 110-112.

van der Kolk JH, Kalsbeek HC, van Garderen E et al. Equine pituitary neoplasia: a clinical report of 21 cases (1990-1992). *Vet Rec* 1993; 133: 594-597.

van der Kolk JH, Wensing T, Kalsbeek HC et al. Laboratory diagnosis of equine pituitary pars intermedia adenoma. *Domest Anim Endocrinol* 1995; 12: 35-39.

Vanschandevijl K, Gielen I, Nollet H et al. Computed tomography-guided brain biopsy for in-vivo diagnosis of a cholesterinic granuloma in a horse. *J Am Vet Med Assoc* 2008; 233: 950-954.

Vitums A. Observations on the equine hypophyseal portal system. *Anat, Histol, Embryol* 1975; 4: 149-161.

Vitums A. Development of venous drainage of equine hypophysis cerebri. *Anat, Histol, Embryol* 1978; 7: 120-128.

Welsh CE, Duz M, Parkin TDH et al. Prevalence, survival analysis and multimorbidity of chronic diseases in the general veterinarian-attended horse population of the UK. *Prev Vet Med* 2016; 131: 137-145.

CHAPTER 2

EQUINE PITUITARY PARS INTERMEDIA DYSFUNCTION: AN INTERNATIONAL SURVEY OF VETERINARIANS' APPROACH TO DIAGNOSIS, MANAGEMENT AND ESTIMATED PREVALENCE

CHAPTER 2

TRANSITION PAGE

Equine pituitary pars intermedia dysfunction: An international survey of veterinarians' approach to diagnosis, management and estimated prevalence

This chapter presents an international survey completed by equine practitioners from 20 countries. This serves as a basis upon which to investigate PPID further. Important geographical differences were found in the methodology of diagnosis. Cost and management responsibilities associated with treatment were described as client concerns by veterinarians completing the survey.

This survey was important to bring an international perspective to the diagnosis and management of this chronic equine condition. Additionally, it verifies the need for either a long-acting therapy, or a 1-time treatment, to bring about a cure and improve the welfare of aged horses.

Copyright statement: Chapter 2 has been submitted for publication. The copyright of this Chapter will belong to the journal in which it is published.

Full citation: Carmalt JL, Waldner CL and Allen AL. Equine pituitary pars intermedia dysfunction: An international survey of veterinarians' approach to diagnosis, management and reported prevalence. Can J Vet Res, 2017. Accepted.

Author contributions: Carmalt and Allen were responsible for the experimental design. Carmalt and Waldner were responsible for data analysis. Carmalt wrote the manuscript with Waldner and Allen providing editorial assistance.

2.1 ABSTRACT

Objectives: To determine if the diagnosis and treatment of pituitary pars intermedia dysfunction (PPID) varies by geographic region and to estimate the prevalence of PPID in horses as observed by veterinarians across locations.

Materials and Methods: An online questionnaire was developed for equine veterinarians. Veterinary associations, especially equine specialty sub-groups, were contacted and a survey link was sent to members of each organization. Generalized linear models were used to examine whether the method of diagnosis and treatment of this condition, as well as reported prevalence, differed by geographic region.

Results: 426 veterinarians from separate clinics completed surveys. Diagnosis was usually based on clinical signs and an endogenous adrenocorticotrophic hormone test. Treatment was typically medical (63% of respondents) of which 75% used pergolide mesylate. The estimated prevalence was 1% which did not differ by geographical location. Half of veterinarians had 5 or more animals with PPID under their care.

Conclusions: Geographic differences exist in the diagnostic approach, but not the estimated prevalence of clinical disease. Cost and management responsibilities associated with treatment were described as client concerns by veterinarians.

2.2 INTRODUCTION

Pituitary pars intermedia dysfunction (PPID), also known as equine Cushing's disease, is a commonly diagnosed endocrinopathy of older horses (Toribio 2005). Clinical signs are typically noted in horses older than 18 years and are rare in horses under 10 (Schott 2002; Orth et al. 1982).

The estimated prevalence of PPID is varied and depends on the age of horses in the referent population, as well as the method (i.e., owner reports versus diagnostic tests) used to effect the diagnosis (Table 1.1). Johnson et al. (2011) state that "conservative estimates of the prevalence of the condition range from 0.07% to 0.5% of the equine population", and Rohrbach et al. (2012) report an increase in the rate of diagnosis from 0.025% to 0.37% between 1993 and 2002. However, as the horse population ages, the prevalence increases: 3.3% in horses over 15 years in Great Britain (Ireland et al. 2011), 10% in horses over 20 years in North America (Brosnahan and Paradis 2003) and 14% to 21% in similarly aged horses in Australia (McGowan et al. 2013).

The proposed pathophysiology of PPID is a loss of dopaminergic inhibition of melanotrophs in the pars intermedia of the pituitary gland leading to hyperplasia and hypertrophy. The inciting cause is unknown, but oxidative damage to the hypothalamic dopaminergic neuronal soma is thought to play an important role (McFarlane et al. 2005; Glover et al. 2009). The prevalence of Parkinson's disease, a human dopamine-associated neurodegenerative disorder, varies among geographic regions with higher prevalence in northern and agricultural North American states compared to southern and industrialized areas (Priyadarshi et al. 2001; Wright 2010). It is

unknown if such a geographical effect exists for equine PPID, whether it be regional or global.

Domesticated horses are living longer as they are increasingly being managed as companion animals (Welsh et al. 2016). As such, the frequency with which veterinarians are asked to diagnose and manage PPID would be expected to rise. The objectives of the study were to determine whether veterinarians were diagnosing and treating this important chronic disease in similar fashion across different geographical regions while accounting for any differences veterinarians reported in estimated prevalence of PPID.

2.3 MATERIALS AND METHODS

A survey was developed (Appendix A) and pilot tested with veterinarians experienced in the design and implementation of survey tools. The final product was translated into French and Spanish and all 3 versions were managed online for 18 months (January 2012 to June 2013)^a. Institutional ethics approval was not required because no personal data was requested from respondents.

The survey was brought to the attention of equine practitioners by contacting international colleagues, national and state (USA and Australia) or provincial (Canadian) veterinary organizations, as well as international equine veterinary groups, including equine sub-specialties of the national associations of individual countries (Appendix B). These groups then notified their respective members through e-mail, digital bulletins and newsletters. Six months after original contact, all groups were asked to send a second notification to their membership. Paper

surveys were also produced and distributed by the authors at the annual meeting of the American Association of Equine Practitioners (2012; Anaheim, California) and completed results were added to the database. All results were compiled using a Windows-based spreadsheet program^b and then moved to a commercial statistical package for analysis^c.

Linear regression was first used to look at differences in practice-level prevalence reported by veterinarians as a percentage of their caseload (denominator not available) by both practice type and among geographic regions, as this was considered a factor that might subsequently impact approaches to diagnosis and treatment. Poisson regression with a log link function was used to examine the effect of potential risk factors on the number of PPID diagnostic tests used by veterinarians. Logistic regression was used to evaluate potential risk factors for the decision to use a diagnostic test (1) in addition to clinical signs alone (0); similarly, to determine the potential risk factors behind the decision to use the most common endocrinologic test (1) as opposed to other endocrinologic test options (0); whether the primary disease – what is assumed to be a functional pituitary tumor – was treated (1) or not (0); and if treated with commercial (1) versus compounded (0) pergolide (if available). All potential risk factors were initially screened using unconditional analysis and variables where p-values < 0.2 were considered in building the final multivariable model (Dohoo, Martin and Stryhn 2012). All final models were built using manual backwards elimination. Variables considered in model building that were not significant, and that were not mediators, were assessed as potential confounders of associations of interest that were identified during the analytical process. Where 2 or more variables were significant, biologically plausible 2-way interactions were assessed with interactions retained in the final model and reported if the type-3 likelihood ratio test was significant ($p < 0.05$). Differences,

where $p < 0.05$ were considered significant, and appropriate measures of effect and 95% Confidence interval (CI) were reported for each analysis.

The number of horses under the care of veterinary practitioners was highly skewed and associations between this variable and the outcomes of interest were not linear. As such, the number of horses under the care of each veterinarian was categorized using cut-off limits based on the 25%, 50% and 75% data quartiles as follows: 1 to 2 horses, 3 to 4 horses, 5 to 20 horses, and 21 to 250 horses.

Not all questions were answered by all respondents. For other questions, such as country of veterinary practice and practice type, there was only 1 respondent from each of South Africa, Chile and Jordan. Countries were consolidated into geographical regions (Table 2.1) for analysis with elimination of single respondent regions. For these reasons not all analyses had the same number of included observations. Specific inclusion criteria and respondent numbers are reported in the appropriate sections of the results.

2.4 RESULTS

There were 426 respondents each representing a single clinic; 404 responded in English, 12 responded in French and 10 responded in Spanish. Two hundred and eighty-seven respondents (67.4%) from 20 countries completed the question on practice location of whom the majority,

Table 2.1 Number of veterinary responses tabulated by country and grouped by geographic region.

Geographic Region	Country	Total number of respondents from each country	Percent of total number	Percent of total number of reported practice country
North America		181	42.5	63
	Canada	83	19.5	28.9
	USA	98	23	34.1
South America		1	0.2	0.3
	Chile	1	0.2	0.3
Europe		73	17.2	25.3
	Belgium	6	1.4	2.1
	Denmark	5	1.2	1.7
	France	3	0.7	1
	Germany	30	7	10.5
	Italy	2	0.5	0.7
	Netherlands	2	0.5	0.7
	Northern Ireland	1	0.2	0.3
	Norway	2	0.5	0.7
	Portugal	2	0.5	0.7
	Spain	6	1.4	2.1
	Sweden	5	1.2	1.7
	United Kingdom	9	2.1	3.1
Middle East		1	0.2	0.3
	Jordan	1	0.2	0.3
Australasia		31	7	10.4
	Australia	23	5.4	8
	Japan	4	0.9	1.4
	New Zealand	3	0.7	1
Africa		1	0.2	0.3
	South Africa	1	0.2	0.3
	Reported	287	67.4	100
	Unreported	139	32.6	
	Total	426	100	

34.1% (98/287), were from the U.S.A, 28.9% (83/287) were from Canada, and 10.5% (30/287) were from Germany. Countries were grouped into geographical regions (Table 2.1). Practice category was widely varied (Table 2.2) and encompassed equine specialists as well as combined small animal and equine practitioners, and general mixed animal veterinarians. Most respondents worked in private practice (Table 2.3).

Of the 426 veterinarians completing the survey, 360 (84.5%) reported at least 1 horse with PPID in their practice. The median number of PPID animals under the care of the study respondents was 5 (25% and 75% IQ range 3 to 20). These animals represented a median of 1.0% (25% and 75% IQ range 0.1 to 5.0) of their equine practice case-load. The median age of affected horses was 20 years (25% and 75% IQ range 18 to 22; mean 19.7 +/- SD 4.3, range 9 to 35 years).

Overall, 67.2% (242/360) of veterinarians reported managing PPID horses by treating, what was assumed to be a functional pituitary tumor, with drugs. Of the remaining 32.8% (118/360), only 34 of the respondents elaborated as to why they offered no treatment. Seventy-nine percent (27/34) of these veterinarians indicated that client limitations prevented the clients from treating, while treatment was not warranted in 17% (6/34), or the lack of drug availability prevented them from treating (3%, 1/34). Reasons for client limitations were reported as financial (66.7%; n = 25) or perceived responsibility of long-term management (33.3%; n = 14). Some respondents reported that both financial and responsibility of long-term management were limiting reasons.

Table 2.2 Distribution of respondents by practice categories

Practice Category	Number	Overall Percentage	Percentage of Reported Practice Categories
Equine only (Specialty)	132	31.0	44.0
Large Animal (Equine Predominant)	40	9.4	13.3
Large Animal (General)	16	3.8	5.3
Combined SA and Equine	47	11.0	15.7
General Mixed	65	15.3	21.7
Reported	300	70.4	100.0
Unreported	126	29.6	
Total	426	100.0	

Table 2.3 Distribution of respondents by practice type

Practice Type	Number of Respondents	Overall Percentage	Percentage of Reported Practice Types
Private Practice	274	64.3	92.6
Academia	17	4.0	5.7
Government	3	0.7	1.0
Industry	2	0.5	0.7
Reported	296	69.5	100.0
Unreported	130	30.5	
Total	426	100.0	

Of those veterinarians with at least 1 PPID horse under their care, 67.2% (242/360) recommended medical treatment, while a small number reported using other options such as dietary management (8), herbal therapy (4), exercise (3), acupuncture (3), immunomodulation (2), and parasite management (1). Some chose not to treat (46/360) and some respondents (66/360) did not describe their treatment recommendations.

Additionally, other veterinarians reported using different management strategies in some cases (hence the numerator is greater than the denominator), but did not elaborate as to what influenced their choices. Overall, pergolide mesylate was the most commonly reported form of medical treatment ($n = 271$) as either the compounded (136) or commercially available (135) form. Commercial cyproheptadine (6), trilostane (5), and bromocriptine (2) were also used. Some veterinarians reported using more than 1 product on the same horse and, therefore, the sum of treatments exceeds the number of respondents.

Most respondents (71.0%, 303/426) indicated that they thought PPID was an important equine disease. Fifty-four percent of veterinarians (228/426) indicated that a new approach to the management or cure of the disease was necessary.

The dataset was then limited to veterinarians working in private and academic practice in North America and Europe ($n = 254$). None of the variables examined, including geographical region ($p = 0.61$) or practice type ($p = 0.61$), were associated with the estimated prevalence of disease. Similarly, the number of animals reported as being under the care of each respondent did not vary by geographic region ($p = 0.96$). The number of animals under care did vary by practice category

($p = 0.004$), where those respondents in equine only (specialty) practice had more PPID horses under their care than veterinarians in mixed small animal / equine practices and general practice ($p = 0.002$ and 0.001 , respectively). There was no difference between those in large animal / equine ($p = 0.15$) or large animal practice ($p = 0.64$), and there were no significant differences among other categories.

Equine veterinarians from North America and Europe that have PPID horses under their care ($n = 208$) typically used a single diagnostic test to determine whether a horse had PPID (median 1, 25% and 75% IQ range 1 to 2; mean 1.4 ± 0.63 , range 1 to 4), and this number varied by geographical location ($p = 0.046$), but not based on the characteristics of the practice surveyed ($p = 0.13$). Some respondents reported using clinical signs as their only diagnostic test (56/208, 27%). In the final model of factors affecting whether a practitioner used only clinical signs, or clinical signs and an additional test to diagnose PPID, the only significantly associated variable was geographical location ($p = 0.01$). The odds of European veterinarians using clinical signs alone to diagnose PPID was higher than for North American veterinarians (OR 5.35, 95% CI = 2.1 to 14.2).

If veterinarians chose to use a diagnostic test in addition to clinical signs, the most common adjunct test was a determination of endogenous adrenocorticotrophic hormone (ACTH) concentrations. The final model identifying the factors associated with whether a practitioner chose to diagnose PPID using clinical signs and endogenous ACTH compared to clinical signs and any other additional test included only the number of horses under the care of the veterinarian. Veterinarians with less than 5 horses with PPID under their care were more likely to

use endogenous ACTH, as compared to another test, in addition to clinical signs than those veterinarians with greater than 5 horses (OR = 5.0, 95% CI = 1.3 to 18.9, p = 0.009).

None of the factors examined, including geographical region (p = 0.31), were associated with whether a respondent decided to treat PPID medically as compared to leaving the horses untreated. North American and European respondents' choice of drug to treat PPID included commercial pergolide mesylate (n = 100), compounded pergolide mesylate (n = 98), cyproheptadine (n = 5), commercial trilostane (n = 3) and bromocriptine (n = 2). Some respondents used more than 1 drug.

2.5 DISCUSSION

The objectives of this survey were to investigate whether veterinarians in different geographical regions used similar strategies in the diagnosis and treatment of PPID while accounting for any differences in the estimated prevalence of PPID as reported by these veterinarians. We attempted to encourage a wide variety of respondents by actively inviting a spectrum of veterinarians, from those who were in general mixed practice with at least some equine cases to those in specialty practices where 100% of the caseload was equine.

Eighty-four percent of respondents had at least 1 horse with PPID under their care, with half of veterinarians reporting at least 5 horses with PPID. This data shows that most veterinarians servicing the horse industry have to deal with this chronic, debilitating problem. Our results suggest that European veterinarians were more likely to use clinical signs alone for diagnosis than colleagues in North America. The reason behind this difference is intriguing and deserving

of further investigation. By waiting until the pathognomonic clinical appearance of advanced PPID is evident, some European veterinarians might be waiting longer than necessary before instituting treatment to ameliorate the biochemical abnormality associated with this condition. However, given the ready availability of a commercial medical treatment with proven efficacy and few negative sequelae beyond cost for treating an incorrectly diagnosed patient, additional diagnostics could potentially be perceived as not being cost efficient. Unfortunately, the response rate for our study was not sufficient to detect differences, if any, among European countries.

Taking all responses into consideration, 30% of respondents in our survey used clinical signs, i.e., hypertrichosis, as the sole diagnostic criterion in the diagnosis of PPID. This may appear inadequate, however, hypertrichosis has been reported as having a positive predictive value (PPV) of 90% (Frank et al. 2006). This is a high value, but the calculation of PPV is intimately associated with the prevalence of disease. Since the authors of that paper selected their case population as being suspicious of PPID, and then confirmed the diagnosis using post-mortem examination, the prevalence of disease was high (62%). The specificity and sensitivity of the test was reported as 95% and 71%, respectively. In our study population, where veterinarians reported an estimated prevalence of PPID of 1% in their practice populations, the use of hypertrichosis alone would generate a PPV of only 14%. The negative predictive value (NPV) of a lack of hypertrichosis in this population, however, is greater than 99%. The evaluation of hypertrichosis in older horses results in an increased PPV because they have a higher pretest probability of disease (McGowan 2013). The probability of a false positive diagnosis in an aged horse with hypertrichosis should be much lower due, in part, to the limited list of possible alternative diagnoses. Rohrbach et al. (2012) reported that 34% of 44 horses and ponies with

PPID were diagnosed solely on the basis of hypertrichosis, with another 23% based on a combination of hypertrichosis and the result of a dexamethasone suppression test. The authors stated that when present, hypertrichosis was considered as accurate as laboratory-identified cases. However, the sensitivity is not 100% and the resulting NPV in high risk horses will not be greater than 99%. Three percent of horses with a pituitary pars intermedia adenoma at necropsy did not show any clinical signs associated with PPID including hypertrichosis (Okada et al. 1997; van der Kolk et al. 2004).

Dybdal et al. (1994) reported that all PPID horses had a plasma cortisol concentration of greater than 27.6 nmol/L (1 µg/dL) at 20 hours post dexamethasone administration, whereas all control horses had serum cortisol concentrations less than 27.6 nmol/L. Subsequently, Frank et al. (2006) reported that the dexamethasone suppression test had a sensitivity of 65% and a specificity of 76% in a population of horses, whose age ranged from 2 years to 33 years, in which the diagnosis was ultimately determined by necropsy assessment of the pituitary gland. Most respondents to the survey question used resting plasma ACTH concentration (van der Kolk et al. 1995; Couëtil et al. 1996) as their adjunct diagnostic test of choice. This has a reported sensitivity between 80% and 84% with a specificity of between 78% and 83%, using different cut-off values, of 29.7 pg/mL (McGowan et al. (2013) and 35 pg/mL (Perkins et al. (2002), using hypertrichosis and 3 or more clinical signs of PPID in seasons other than autumn. It is important to note that early papers citing diagnostic cut-off values may be misleading as they were published before the seasonal variation in ACTH concentration was recognized (Donaldson et al. 2005). The differences in the specificity and sensitivity of the dexamethasone suppression and the endogenous ACTH tests

may explain why the use of the dexamethasone suppression test, as well as the reported risks of inducing laminitis, has fallen out of favor.

For the aged horse with hypertrichosis, use of an additional test with the above mentioned specificities and sensitivities (the presence of hypertrichosis and endogenous ACTH testing) only decreases the probability of detecting a false positive (1-Specificity) PPID horse from 5% to about 1% assuming serial interpretation of the test results from clinical diagnosis followed by the endogenous ACTH test.^d Depending on the estimated prevalence of the disease in that age of horse, the PPV is not substantially improved by using the combined approach, questioning the benefit of additional testing to rule-in disease in animals with clinical signs. It was interesting to find that veterinarians with fewer than 5 horses under their care were more likely to use laboratory corroborative testing than those with greater than 5 horses. The reasoning behind this choice is not known, however, we speculate that perhaps those with greater numbers of PPID animals under their care are more confident in using only clinical signs, because of their greater professional experience.

One limitation of the data obtained from this survey, as well as that in the existing peer-reviewed literature, is that horses that are both confirmed with, and suspected of having, PPID are discussed together. Historically, horses that did not have hypertrichosis, despite advancing age, were infrequently tested and there is currently no consensus on a definitive diagnostic test for documenting PPID, especially in earlier stages of disease. As such, the true prevalence of disease may be much higher than reported (Donaldson, Jorgensen and Beech 2004; van der Kolk 2004; Rohrbach et al. 2012). The extent to which old horses and ponies, i.e., greater than 15 years, are

being tested has been subjectively increasing in recent years (especially in the UK and Australia, whose numbers are not well represented in the current survey), and there has been an emphasis on trying to detect and treat PPID before it becomes a welfare concern. A recent experimental study by McGowan et al. (2013) reported a PPID prevalence of 21.2% in horses over 15 years, based on endogenous ACTH concentration, despite the prevalence of hypertrichosis being only 14.2%. In this scenario (aged horse with no apparent hypertrichosis), the addition of endogenous ACTH testing interpreted in parallel with clinical signs (again, with the above mentioned specificities and sensitivities) will improve the sensitivity of a diagnosis of PPID from 71% with clinical signs alone, to 95% for animals with a concurrent positive ACTH test.^d This shows that the use of adjunct testing methodologies earlier in the disease process, or as a screening test in horses over 12 to 15 years of age, can allow earlier diagnosis and treatment of disease. This may improve the health of the horse and extend the usefulness of the animal to the client. As a profession, we can and should strive to diagnose this condition earlier and thus improve the quality of life for aging horses.

Most respondents reported treating individuals suspected to be affected with PPID, and most of them used pergolide mesylate. Commercial and compounded product was equally represented overall. Unfortunately, the survey did not explore the extent to which commercial versus compounded form of pergolide was available to the respondents, as this may have significantly affected their choice of product, especially as the compounded pergolide has been shown to have substantial limitations, such as a lack of stability depending on the vehicle and storage conditions (Stanley and DiMaio Kynch 2010; Davis et al. 2009).

Of the small number of participants elaborating as to why they did not treat affected horses almost 80% reported that financial and management limitations reported by their clients precluded treatment. Some veterinarians cited both reasons. This may explain why, despite the availability of a drug with proven efficacy (Munoz et al. 1996; Perkins et al. 2002; Schott et al. 2001; Donaldson et al. 2002; Sgorbini et al. 2004), over 50% of respondents stated that they would like to see a new treatment or cure developed for this debilitating condition. The current treatment is costly due to its ongoing nature, and is labor and management intensive. Treating a horse on a daily basis may not seem overly onerous, however, in extensively or pasture managed horses who are infrequently handled, the need for daily medication would preclude treatment. Similarly, there is a significant emotional stress put upon the caregivers of humans and animals with chronic ongoing disease processes (Thompson and Gustafson 1996; Kelly 2014). Earlier diagnosis and treatment of this condition could improve the welfare of the horse by reducing or preventing some of the clinical sequelae, but will do little to assuage the client concerns and emotional stress about the feasibility of daily medication. If an equally efficacious, yet much less labor intensive, treatment were to become available, it is possible that veterinarians and clients would explore this option.

The data from this survey represent the information shared by the veterinarians who were interested enough in this issue to take the time to respond to the survey. Volunteer bias is a limitation of survey data, as it is for the recruitment of practices to provide access to client data. However, the results were not completely restricted to veterinarians with a strong interest in PPID as only 71% reported that it is an important disease.

A second challenge in this study resulted from working through third parties to distribute the survey link. Given that the number of member e-mail addresses for each distributing organization was not shared, the response rate was unable to be calculated. However, despite the increasing focus on privacy and confidentiality of distribution lists, the authors were fortunate that these organizations were willing to distribute the survey link. The number of total respondents was lower than was originally hoped, however, based on the resulting confidence intervals adequate power to explore regional differences and risk factors for important diagnostic and treatment practices was available. Most respondents were from North America, Europe and, to a lesser extent, the Asia-Pacific region. However, as far as the authors are aware, this is the only study to provide a concurrent comparison among these regions. While it may be limited in its accuracy, our data reflect a cross-section of a larger number of clinics and geographical regions than has been previously reported, and suggest that there was not a substantial difference in the perceived prevalence of PPID among participating regions. The reasons for lower numbers of responses from regions other than North America and Europe are unknown.

Finally, there are recall biases inherent in all survey responses, but there is no reason to believe that this would be different among different regions. The estimated prevalence was at greater risk from reporting errors than routine diagnostic and management practices. It was not considered practical to ask veterinarians to do a search of their client records, however, the focus of our discussion has been on diagnostic and treatment choices.

Overall, the results of this international survey of equine veterinarians indicated there were differences in how veterinarians diagnose PPID, with European veterinarians more likely to

render a diagnosis without adjunct laboratory testing, regardless of the number of animals under their care, than North American colleagues. The estimated prevalence of the condition recognized by practitioners was approximately 1% of horses of all ages, with no apparent geographical variation. More specifically, there was no difference in estimated prevalence between the northern and southern hemispheres, and no difference between Canada and the USA. There is a need for additional treatment options for PPID as some veterinarians reported that their clients are concerned about cost and management restrictions surrounding the long-term treatment of PPID.

Footnotes:

^a Vertical Response, San Francisco, California, USA

^b Microsoft Excel, Microsoft Canada Inc, Mississauga, ON, Canada

^c SPSS, IBM Canada Inc, Mississauga, ON, Canada

^d <http://epitools.ausvet.com.au/content.php?page=2Tests>

2.6 REFERENCES

Brosnahan MM and Paradis MR. Demographic and clinical characteristics of geriatric horses: 467 cases (1989-1999). *J Am Vet Med Assoc* 2003; 223: 93-98.

Cout il L, Paradis MR, Knoll J. Plasma adrenocorticotropin concentration in healthy horses and in horses with clinical signs of hyperadrenocorticism. *J Vet Intern Med* 1996; 10: 1-6.

Davis JL, Kirk LM, Davidson GS, Papich MG. Effects of compounding and storage conditions on stability of pergolide mesylate. *J Am Vet Med Assoc* 2009; 234: 385-389.

Dohoo I, Martin W, Stryhn H. Model-building strategies. In: *Veterinary Epidemiologic Research*, 2nd edn., VER Inc. Charlottetown, Prince Edward Island, CANADA 2012; pp 365-394.

Donaldson MT, Jorgensen AJ, Beech J. Evaluation of suspected pituitary pars intermedia dysfunction in horses with laminitis. *J Am Vet Med Assoc* 2004; 224: 1123-1127.

Donaldson MT, LaMonte BH, Morresey P et al. Treatment with pergolide or cyproheptadine of pituitary pars intermedia dysfunction (equine Cushing's disease). *J Vet Intern Med* 2002; 16: 742-746.

Donaldson MT, McDonnell SM, Schanbacher BJ et al. Variation in plasma adrenocorticotrophic hormone concentration and dexamethasone suppression test results with season, age, and sex in healthy ponies and horses. *J Vet Intern Med* 2005; 19: 217-222.

Dybdal N, Hargreaves KM, Madigan JE et al. Diagnostic testing for pituitary pars intermedia dysfunction in horses. *J Am Vet Med Assoc* 1994; 204: 627-632.

Frank N, Andrews FM, Sommardahl CS et al. Evaluation of the combined dexamethasone suppression / thyrotropin -releasing hormone stimulation test for the detection of pars intermedia pituitary adenomas in horses. *J Vet Intern Med* 2006; 20: 987-993.

Glover CM, Miller LM, Dybdal NO et al. Extrapituitary and pituitary pathological findings in horses with pituitary pars intermedia dysfunction: a retrospective study. *J Equine Vet Sci* 2009; 29: 146-153.

Ireland JL, Clegg PD, McGowan CM et al. A cross-sectional study of geriatric horses in the United Kingdom. Part 2: Health care and disease. *Equine Vet J* 2011; 43: 37-44.

Johnson PJ, Messer NT, Ganjam VK. Pituitary pars intermedia dysfunction (equine cushing's syndrome). In: *Equine reproduction* 2nd edn. McKinnon AO, Squires L, Vaala WE, Varner DD Eds. Ames, Iowa. Wiley-Blackwell 2011; 2790-2795.

Kelly MA. Managing a Pet's Chronic Illness: Factors that Influence Psychosocial Adjustment. PhD thesis, University of Illinois, 2014

McFarlane D, Dybdal N, Donaldson MT et al. Nitration and increased alphasynuclein expression associated with dopaminergic neurodegeneration in equine pituitary pars intermedia dysfunction. *J Neuroendocrinol* 2005; 17: 73-80.

McGowan TW, Pinchbeck GP, McGowan CM. Evaluation of basal plasma a-melanocyte-stimulating hormone and adrenocorticotrophic hormone concentrations for the diagnosis of pituitary pars intermedia dysfunction from a population of aged horses. *Equine Vet J* 2013; 45: 66-73.

McGowan TW, Pinchbeck GP and McGowan CM. Prevalence, risk factors and clinical signs predictive of pituitary pars intermedia dysfunction in aged horses. *Equine Vet J* 2013; 45: 74-79.

Munoz MC, Doreste F, Ferrer O et al. Pergolide treatment for Cushing's syndrome in a horse. *Vet Rec* 1996; 139: 41-43.

Okada T, Shimomuro T, Oikawa M et al. Immunocytochemical localization of adrenocorticotrophic hormone-immunoreactive cells of the pars intermedia in Thoroughbreds. *Am J Vet Res* 1997; 58: 920-924.

Orth DN, Holscher MA, Wilson MG et al. Equine Cushing's disease: plasma immunoreactive proopiomelanocortin peptide and cortisol levels basally and in response to diagnostic tests. *J Endocrinol* 1982; 110: 1430-1441.

Perkins GA, Lamb S, Erb HN et al. Plasma adrenocorticotropin (ACTH) concentrations and clinical response in horses treated for equine Cushing's disease with cyproheptadine or pergolide. *Equine Vet J* 2002; 34: 679-685.

Priyadarshi A, Khuder SA, Schaub EA et al. Environmental risk factors and Parkinson's disease: a metaanalysis. *Environ Res* 2001; 86: 122-127.

Rohrbach BW, Stafford JR, Clermont RSW et al. Diagnostic frequency, response to therapy, and long-term prognosis among horses and ponies with pituitary pars intermedia dysfunction, 1993-2004. *J Vet Intern Med* 2012; 26: 1027-1034.

Schott HC. Pituitary pars intermedia dysfunction: Equine Cushing's disease. *Vet Clin Equine* 2002; 18: 237-270.

Schott HC, Coursen CL, Eberhart SW et al. The Michigan Cushing's project. In: *Proc Ann Con Am Assoc Eq Pract*. 2001; 47: 22-24.

Sgorbini M, Panzani D, Maccheroni M et al. Equine Cushing-like syndrome: diagnosis and therapy in two cases. *Vet Res Commun* 2004; 28(Suppl 1): 377-380.

Silva AG and Furr M. Diagnosis, clinical pathology findings, and treatment outcome of geriatric horses: 345 cases (2006-2010). *J Am Vet Med Assoc* 2013; 243: 1762-1768.

Stanley SD, DiMaio Knych H. Comparison of pharmaceutical equivalence for compounded preparations of pergolide mesylate. *Proc Ann Con Am Assoc Eq Pract* 2010; 65: 274-276.

Thompson RJ, Gustafson KE. *Adaptation to chronic illness*. Washington, DC: American Psychological Association 1996.

Toribio RE. Diagnosing equine pars intermedia dysfunction: Are we there yet ? *J Vet Intern Med* 2005; 19: 145-146.

van der Kolk J, Heinrichs M, van Amerongen JD et al. Evaluation of pituitary gland anatomy and histopathologic findings in clinically normal horses and horses and ponies with pituitary pars intermedia adenoma. *Am J Vet Res* 2004; 65: 1701-1707.

van der Kolk J, Wensing T, Kalsbeek HC et al. Laboratory diagnosis of equine pituitary pars intermedia adenoma. *Domest Anim Endocrinol* 1995; 12: 35-39.

Welsh CE, Duz M, Parkin TDH et al. Prevalence, survival analysis and multimorbidity of chronic diseases in the general veterinarian-attended horse population of the UK. *Prev Vet Med*. 2016; 131: 137-145.

Wright WA, Evanoff BA, Lian M et al. Geographic and ethnic variation in Parkinson disease: a population based study of US Medicare beneficiaries. *Neuroepidemiol* 2010; 34: 143-151.

CHAPTER 3

PROFILES OF PRO-OPIOMELANOCORTIN, ENCODED PEPTIDES, AND THEIR PROCESSING ENZYMES IN EQUINE PITUITARY PARS INTERMEDIA DYSFUNCTION

CHAPTER 3

TRANSITION PAGE

Profiles of pro-opiomelanocortin, encoded peptides, and their processing enzymes in equine pituitary pars intermedia dysfunction

This chapter presents the results of sequencing the equine POMC, PC1 and PC2 genes. The most appropriate internal reference gene for the equine pituitary gland is described, as is the expression of POMC, PC1 and PC2 in PPID and normal horses. The concentration of POMC, ACTH, α MSH, CLIP, PC1 and PC2 in ventral cavernous sinus plasma of PPID and normal horses is reported.

This work contributes to the understanding of the pathophysiology of PPID by confirming previously held assumptions that upregulation of PC1 and PC2 occurs in PPID. Partial sequences of POMC, PC1 and PC2 were submitted to GenBank, where previously there had only been computer predictions. Pituitary hormone concentrations confirmed upregulation in PPID, but used samples obtained from the ventral cavernous sinus resulting in values that were much higher than have previously been reported.

Copyright statement: Chapter 3 has been submitted for publication. The copyright of this Chapter will belong to the journal in which it is published.

Full citation: Carmalt JL, Mortazavi S, McOnie R, Allen AL and Unniappan S. Profiles of pro-opiomelanocortin, encoded peptides, and their processing enzymes in equine pituitary pars intermedia dysfunction. PLOS ONE, 2017. Submitted.

Author contributions: Carmalt, Allen and Unniappan were responsible for experimental design. Mortazavi and McOnie performed the sequencing, RT- and conventional PCR work. The protein portion was performed by Carmalt, Sue Cook and Kim Tran. Carmalt and Mortazavi wrote the manuscript with editorial input from Unniappan.

3.1 ABSTRACT

Objectives: To identify the partial sequences of equine POMC, PC1, and PC2 mRNAs; and to determine whether the expression of POMC, PC1, and PC2 mRNAs in whole pituitary extracts, and POMC-protein in the cavernous sinus blood of horses are altered in PPID.

Materials and Methods: Total RNA was extracted from the entire pituitary glands of 6 normal and 6 PPID affected horses. cDNA was generated and RT-PCR was used to generate sequences which were subsequently extracted, purified and sequenced. Nine internal control genes were screened for suitability for use in the pituitary gland. cDNA was amplified using primers based on predicted *Equus caballus* sequences for POMC, PC1 and PC2, and subjected to RT-qPCR to determine expression between normal and PPID horses. Commercial ELISAs (POMC, ACTH, CLIP) and a RIA (α MSH) were used to determine plasma concentrations in the ventral cavernous sinus blood.

Results: Partial sequences obtained match the corresponding regions of predicted equine POMC, PC1 and PC2 sequences. The expression of POMC, PC1 and PC2 mRNAs were found upregulated in the pituitary of horses with PPID. Plasma ACTH and α -MSH were elevated, while CLIP was lower in PPID horses.

Conclusions: There are distinct differences in gene and protein expression of POMC and its intermediates, and processing enzymes in PPID. This data provides evidence to support the notion that local, pituitary-specific inadequacies in prohormone processing likely contribute to equine PPID.

3.2 INTRODUCTION

Equine pituitary pars intermedia dysfunction (PPID), also known as equine Cushing's disease, is a common disease of horses older than 15 years. It is the most common endocrine disease of the equine species with reported prevalence between 14% and 30% in aged horses (McGowan et al. 2013). Horses with PPID suffer significant morbidity and chronically poor welfare from myriad clinical signs. Hypertrichosis, chronic recurrent laminitis and redistribution of body fat occur frequently, as does increased susceptibility to opportunistic infections of the skin and respiratory tract. PPID is proposed to be a primary neurodegenerative disorder characterized by a lack of dopaminergic inhibition of the melanotrophs of the pars intermedia (Millington et al. 1988; McFarlane et al. 2005). *In vitro* and *in vivo* studies in rats and sheep have shown that in the absence of dopamine, hyperplasia and hypertrophy of the melanotroph cell line occur (Gehlert et al. 1988; Engler et al. 1990). In mice with dopamine type-2 (D2R) receptor deficiencies, the gene expression of proopiomelanocortin (POMC) and its associated prohormone convertases (PC1 and PC2) are upregulated (Saiardi et al. 1988). This results in an overabundance of downstream POMC-peptides, such as adrenocorticotrophic hormone (ACTH) cleaved from POMC by PC1; and alpha-melanocyte stimulating hormone (α -MSH) and corticotrophin-like immune peptide (CLIP) cleaved from ACTH by PC2, being released into the systemic circulation. This theory is given additional support by the fact that clinical signs and endogenous ACTH levels normalize in the face of treatment with a dopamine agonist (pergolide mesylate).

We hypothesized that PC1 and PC2 levels in the pituitary gland are altered in PPID, resulting in an abnormal relative abundance of POMC derived proteins. Our aims were to confirm the native

cDNA sequences of equine POMC, PC1 and PC2; to determine the most reliable internal control gene for use when quantifying mRNA expression of POMC, PC1 and PC2 in the pituitary; to quantify and compare the mRNA expression of POMC and PCs in normal and PPID horses; and to quantify the plasma concentrations of POMC, ACTH, α -MSH and CLIP in the blood from the ventral cavernous sinus of normal and PPID horses.

3.3 MATERIALS AND METHODS

3.3.1 ANIMALS

The whole pituitary gland of 10 normal and 6 PPID horses, submitted to the Department of Veterinary Pathology at the Western College of Veterinary Medicine, University of Saskatchewan, were collected immediately post-mortem. The gland was diced into small pieces and snap frozen in liquid nitrogen. Samples were stored at -80° C until total RNA extraction. Normal horses comprised of 4 geldings, one stallion, and 5 mares with a mean age of 10.1 years. The PPID horse group, which exhibited the classical signs of disease (hypertrichosis, laminitis and fat redistribution), comprised of 2 geldings and 3 mares (1 sex was not recorded) with a mean age of 22 years. The age disparity between groups was a function of the age-related nature of PPID.

An additional 6 normal horses and 6 PPID horses were used for ventral cavernous sinus blood collection. Normal horses (5 mares and 1 gelding) had a mean age of 12.2 years, whereas the horses exhibiting signs of PPID (5 mares and 1 gelding) had a mean age of 24.3 years. Horses were obtained by private donation to the research program, with signed, informed consent

provided by the owners. They were housed in an outside paddock with hay and water provided *ad-libitum*. Blood was collected from the ventral cavernous sinus of standing horses using techniques reported earlier (Irvine and Alexander 1987). Blood was placed into plastic tubes containing EDTA (1.8 mg/mL), stored on ice during the collection period and then centrifuged at 4000 rpm for 15 minutes at 4° C. Plasma was collected and frozen at -80° C, for further hormone and PC measurements.

3.3.2 TOTAL RNA EXTRACTION AND cDNA SYNTHESIS

Total RNA was extracted from the whole pituitary samples using TRIzol RNA isolation reagent^a. The entire pituitary gland was diced and mixed to prevent including just one region, 1 mL TRIzol was added to 1 mg of diced pituitary tissue samples, and homogenized by bead disruption^b and incubated in room temperature for 5 minutes. Phase separation was performed by adding 200 µL chloroform to each sample. Samples were mixed thoroughly, and centrifuged for 15 minutes at 13000 rpm before the aqueous phase was transferred for RNA precipitation. Isopropanol (500 µL) was added and centrifuged for 15 minutes at 13000 rpm. Pelleted RNA was washed with 1 mL of 75% ethanol and dissolved in pure RNase free water. The purity of extracted RNA was assessed by optical density absorption ratio (OD 260/280 nm)^c. One microgram of total RNA was used for cDNA synthesis using a commercial kit^d as directed by the manufacturer. cDNA samples were stored at -20° C until RT-PCRs and RT-qPCRs.

3.3.3 PRIMERS

Primers were designed using Primer-BlastTM from National Center for Biotechnology Information (NCBI)^e. *Equus caballus* POMC (GenBank: XM_014731265.1), PC1 (GenBank: XM_001504608.4), and PC2 (GenBank: XM_001491591.5) primer sets were designed based on partial predicted sequences with the accession numbers listed above (Table 3.1). Primers were commercially synthesized^f, validated and optimized for high primer efficiency and annealing temperatures. Then, primers were used for Reverse Transcription-Polymerase Chain Reaction (RT-PCR) or Reverse Transcription-Quantitative PCRs (RT-qPCR).

3.3.4 RT-PCR AND SEQUENCING

RT-PCRs were carried out using 1 μ L of cDNA, 50 μ M dNTP's, 10x PCR reaction mix, 2.5 mM MgCl₂ and 0.5 μ L taq DNA polymerase^g making total of 20 μ L of reaction volume. PCR conditions were: initial denaturation for 5 minutes at 95° C followed by 35 cycles of denaturation at 95° C for 1 minute, annealing temperature (Table 3.1) and extension at 73° C for 1 minute, and a final extension of 73° C for 10 minutes. PCR products were electrophoresed on 1.5% agarose gel. The images of the gel were recorded under UV light^h. Bands of the expected size were excised from 1.5% agarose gel. Four bands, representing expected amplicons, were purifiedⁱ and sent for sequencing (National Research Council, Canada). Sequences obtained were analyzed by NCBI and aligned to predicted equine POMC, PC1, and PC2 using NCBI nucleotide blast tools^{j,k}. A comparison of partial sequences from normal and PPID horses to determine whether differences in the critical (mature peptide or enzyme) sites of the sequences was performed.

Table 3.1 Sequences of primers, gene bank accession number, amplicon size, and annealing temperature used for RT-PCR and RT-qPCR.

Gene	Primer	Accession No. GenBank	Amplicon Size (bp)	Annealing Temperature (°C)
POMC	F- CAAGATCGACCTCTCCGCTG*	XM_014731267.1	313	60
	R- GGTCACCTCCACATGGGTGC*		178	61
PC1	F- TGGGTTGCTAAATGCCAAAGC*+	XM_001504608.4	300	60
	R- ACAACCGACTTTCTCTCGCC*+			
PC2	F- TGTGGGGTTCGGAGTAGCATA*	XM_001491591.5	280	60
	R- CCGTCGATGCTGCTGACATT*		168	60
18S rRNA	F- AACGACACTCTGGCATGCTAACT*+	XM_001497064	98	60
	R- CGCCACTTGTCCCTCTAAGAA*+			
GAPDH	F- AGAAGGAGAAAGGCCCTCAG+	NM_001163856	87	56
	R- GGAAACTGTGGAGGTCAGGA+			
B2M	F- GTGTTCCGAAGGTTTCAGGTT+	NM_001082502	102	55
	R- ATTTCAATCTCAGGCGGATG+			
ACTB	F- CGACATCCGTAAGGACCTGT+	NM_001081838	99	56
	R- CAGGGCTGTGATCTCCTTCT+			
GUSB	F- GGGATTGCACTGTGGCTGTCA+	XM_001493514.2	116	62
	R- CCAGTCAAAGCCCTTCCCTCGGA+			
SDHA	F- GCAGAAGAAGCCATTTGAGG+	XM_001490889.4	102	55
	R- CCTGTCGATTACGGGTCTGT+			
YWHAZ	F- TGTTGTAGGAGCCCGTAGGT+	XM_001492988	94	60
	R- ATTCTCGAGCCATCTGCTGT+			
SLC36A2	F- GCTTCTGCCACAGGCTTAAC+	XM_001501324.3	69	55
	R- CCGGCTTTGAGTCCATACAT+			
Cyp19a1	F- GAGATGCCGTGGGAATTCTAGC+	NM_001081805	109	55
	R- ACGTTTCTCAGCCAAAAT+			

*Used for RT-PCR, +Used for RT-qPCR

Once the sequences obtained, although partial, confirmed the predicted sequences, the same primers were used for RT-qPCRs.

3.3.5 RT-QUANTATIVE PCR

cDNAs were amplified by CFX connect¹ (Bio-Rad, Canada) using iQ SYBR green supermix^m, and forward and reverse primers shown in Table 3.1. For each sample, RT-qPCR was run in duplicate and repeated again to ensure consistency. The thermal profile for all reactions was 5 minutes at 95° C and 40 cycles of 10 seconds denaturation at 95° C, 30 seconds of optimum annealing temperature as shown in Table 3.1, and 10 seconds of final extension at 73° C. Specificity of amplified products in RT-qPCR assays were determined by analyzing the melting curve to differentiate the target amplicon from primer dimers and other nonspecific products. A single melt curve was observed for each primer set of all RT-qPCR reactions.

Our extensive search in the literature for a suitable internal control gene that was validated for use in pituitary samples of horses was not successful. The Ct values of glyceraldehyde 3-phosphate dehydrogenase (GAPDH), 18S rRNA (18S), beta- 2-microglobulin (B2M), beta actin (ACTB), succinate dehydrogenase complex (SDHA), beta glucuronidase (GUSB), and tyrosine 3-monooxygenase/tryptophan 5-monooxygenase activation protein (YWHAZ) were examined. These genes were had previously been validated for use in equine reproductive tissues (Klein et al. 2011). Based on the results of this validation, the Ct values of POMC, PC1, and PC2 were normalized to YWHAZ, which had been chosen as the housekeeping gene. Relative mRNA

expressions of genes of interest were determined according to Livak and Schmittegen (2001). All reagents were stored under desired condition until use.

3.3.6 HORMONE MEASUREMENTS

Plasma ACTH concentrations were measured using a commercial sandwich assay^{n,o}. The plasma samples and test controls^p, were thawed and maintained on ice until analysis. Intra-assay coefficients of variation were 4.61% to 0.33% for low and high control sera with mean ACTH concentrations of 31.45 or 460 pg/mL, respectively. The manufacturer's stated analytical sensitivity, lower limit of detection, was 9 pg/mL. Competitive sandwich enzyme-linked immunosorbent assays (ELISAs) were performed for POMC (manufacturer's stated analytical sensitivity was 0.1 ng/mL, intra-assay coefficients of variation were 11.19% to 11.48% for control sera with mean POMC concentrations of 0.39 or 8.08 ng/mL, respectively), and CLIP (manufacturer's stated analytical sensitivity was 5.0 pg/mL; intra-assay coefficients of variation were 5.24% to 5.55% for control sera with mean CLIP concentrations of 57.9 or 483.7 pg/mL, respectively) following manufacturers guidelines^{q,r}. A commercial RIA^s was used for the determination of α -MSH concentrations (manufacturer's stated analytical sensitivity was 5 pg/mL (3 pmol/L), intra-assay coefficients of variation were 0.81% to 5.52% for control sera with mean α -MSH concentrations of 20.5 pg/mL or 125.3 pg/mL (12.3 or 75.2 pmol/L), respectively). Manufacturer's guidelines for the ACTH assay stated no cross-reactivity to α MSH, but a 13-15% cross-reactivity to ACTH (18-39). Information contained with the α MSH RIA stated no cross-reactivity to ACTH and guidelines for the CLIP ELISA stated that "no significant cross-reactivity or interference between this analyte and analogues is observed".

3.3.7 STATISTICAL ANALYSIS

All values were reported as means \pm SEM. Statistical analysis was performed using PRISM 5.0[†] and SPSS[‡]. Comparisons between groups were made using Student's t-test (and a Mann-Whitney U test where appropriate). P values < 0.05 were considered statistically significant.

3.4 RESULTS

Partial mRNA sequences of POMC, PC1 and PC2 were obtained and found to be identical to the predicted equine sequences used to design the primers. It also confirmed the hormone-encoding region in the native equine POMC (GenBank Accession number: KY275178), and sequences of PC1 (GenBank Accession number: KY275179), and PC2 (GenBank Accession number: KY275180) mRNA sequences. *Equus* POMC partial nucleotide sequence exhibited high similarity to corresponding regions in the predicted horse (*Equus caballus* 95%), and human (*Homo sapiens*, 85%) POMC nucleotide sequences. The partial amino acid sequences of POMC, α MSH and CLIP were also highly similar to predicted horse (*Equus caballus* 90%, 69.2%, and 91.9% respectively) and human (*Homo sapiens*, 80%; 69.2% α MSH; 10% CLIP) sequences (Figure 3.1A). Additionally, PC1 (Figure 3.1B) and PC2 (Figure 3.1C) partial sequences showed very high similarity to predicted horse (*Equus caballus*, 99% and 98%, respectively) and human (*Homo sapiens*, 98%, 96%, respectively) PC1 and PC2 nucleotide sequences. Horse PC1 and PC2 partial amino acid sequences were found to be identical to predicted horse (*Equus caballus* 99% and 100%, respectively) and human (98%, 100%, respectively) sequences. When comparing the amino acids sequences, we did not find any differences in POMC, PC1 or PC2

Figure 3.1A Equine POMC partial amino acid sequence compared to predicted *Equus caballus* and *Homo sapiens* sequences. Red arrow denotes the cleavage point within POMC for ACTH (the first 13 amino acids of which become α MSH (red line), and the latter amino acids (14-39)) subsequently become CLIP (red arrow with dashed end).

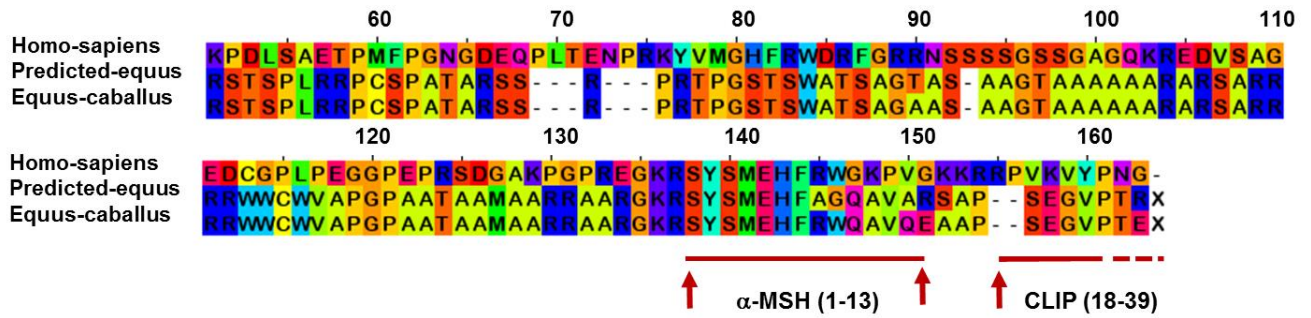


Figure 3.1B Equine PC1 partial amino acid sequence compared to predicted *Equus caballus* and *Homo sapiens* sequences.

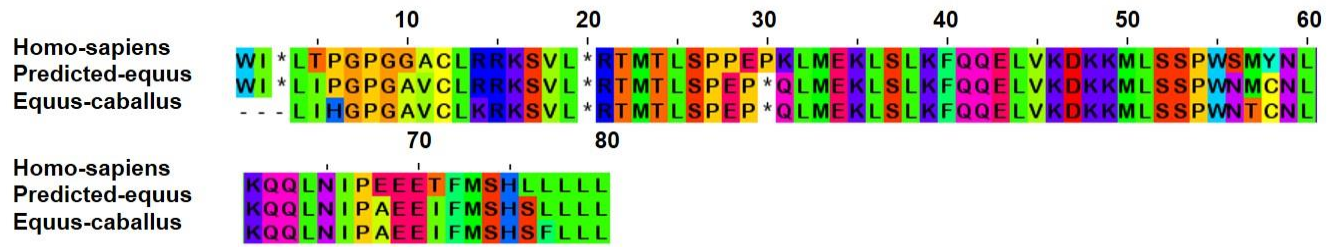
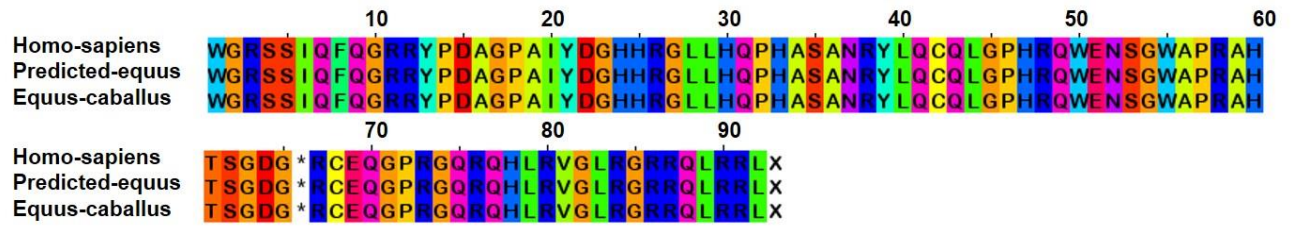


Figure 3.1C Equine PC2 partial amino acid sequence compared to predicted *Equus caballus* and *Homo sapiens* sequences.



sequences between normal and PPID horses.

Of the 9 genes tested as internal control genes (Figure 3.2A), only 18S rRNA (Figure 3.2B), and YWHAZ (Figure 3.2C) genes were found to be stable, and provided consistent Ct values in control and PPID groups. Other genes were not stable, provided inconsistent Ct values and were considered not reliable for use.

POMC, PC1 and PC2 mRNAs were expressed in the equine pituitary gland tissue (Figure 3.3A). POMC (4.8 fold increase, $p = 0.0083$), PC1 (5.45 fold increase, $p = 0.0007$), and PC2 (5.27 fold increase, $p = 0.011$) mRNAs were significantly upregulated in the pituitary gland of horses with PPID ($n = 6$), when compared to normal horses (Figure 3.3B, C, and D, $n = 10$). There was no significant difference between the upregulation of PC1 and PC2 ($p = 0.11$) in PPID horses.

There were no differences in POMC plasma concentrations between normal ($n = 6$) and PPID horses ($n = 6$, $p = 0.68$, Figure 3.4A). ACTH ($p = 0.0005$, Figure 3.4B) and α -MSH ($p = 0.004$, Figure 3.4C) plasma concentrations were significantly higher in PPID horses whereas CLIP ($p = 0.025$, Figure 3.4D) concentrations were significantly lower in PPID horses.

Figure 3.2A Cycle threshold (Ct) values for all 9 internal control genes in the equine pituitary gland. Bars denote mean values (+/- SEM).

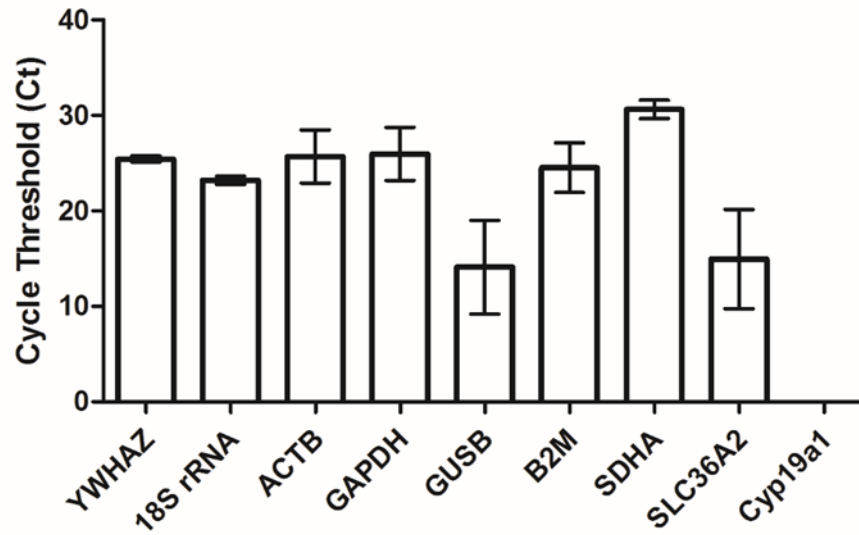


Figure 3.2B Cycle threshold (Ct) values for the mRNA expression of 18S rRNA in the pituitary gland of normal (n = 10) and PPID (n = 6) horses. Bars denote mean values (\pm SEM).

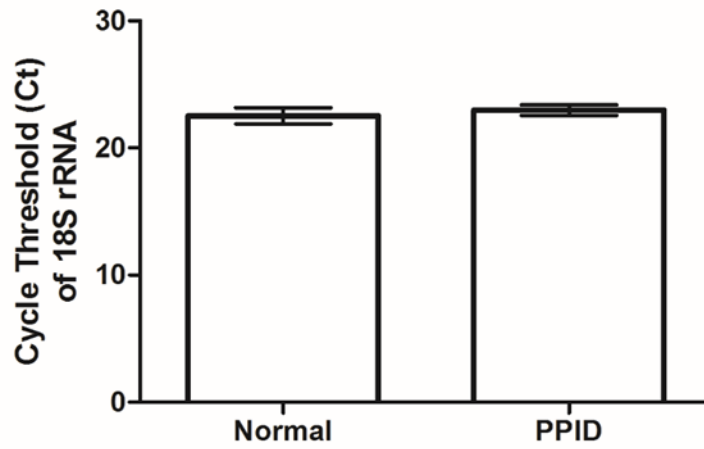


Figure 3.2C Cycle threshold (Ct) values for the mRNA expression of YWHAZ in the pituitary gland of normal (n = 10) and PPID (n = 6) horses. Bars denote mean values (\pm SEM).

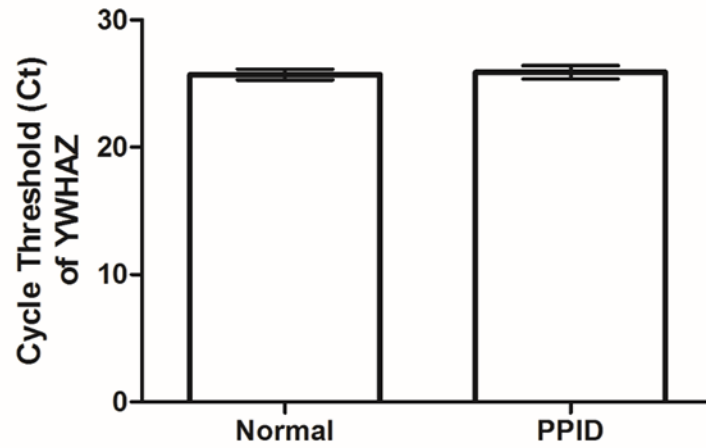


Figure 3.3A A RT-PCR gel electrophoresis image showing the expression of equine POMC (178bp), PC1 (300bp) and PC2 (168bp) in the pituitary gland. NC denotes no-template control for the peptide to the left of the column.

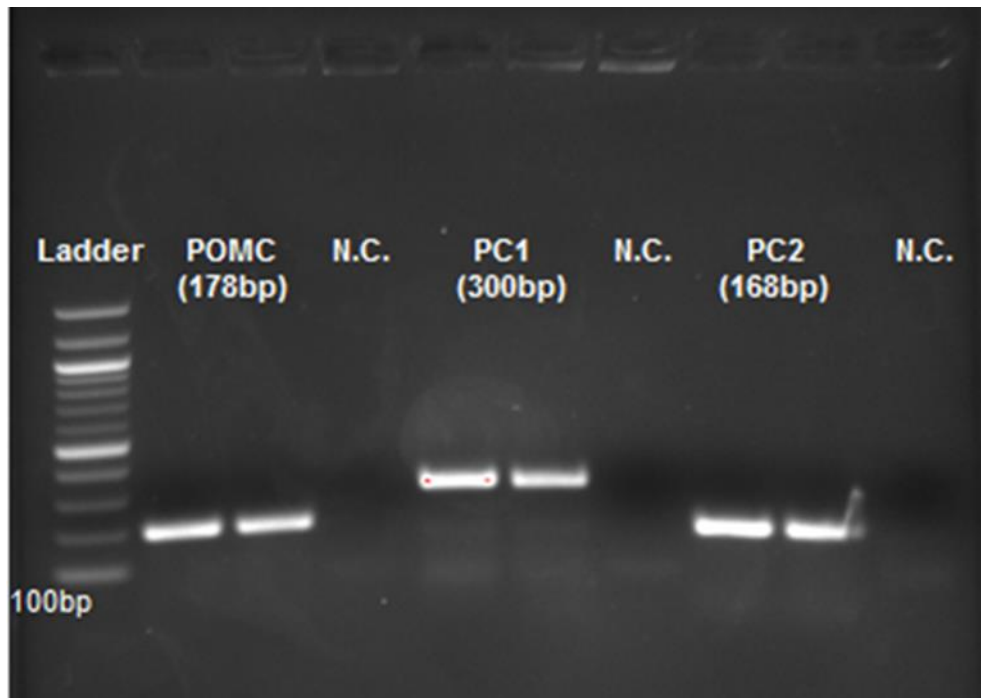


Figure 3.3B POMC mRNA expression in the equine pituitary gland tissue from normal (n = 10) and PPID (n = 6) horses. Data are normalized to the YWHAZ house-keeping (HK) gene. Bars denote mean values (+/- SEM). ** = p < 0.01.

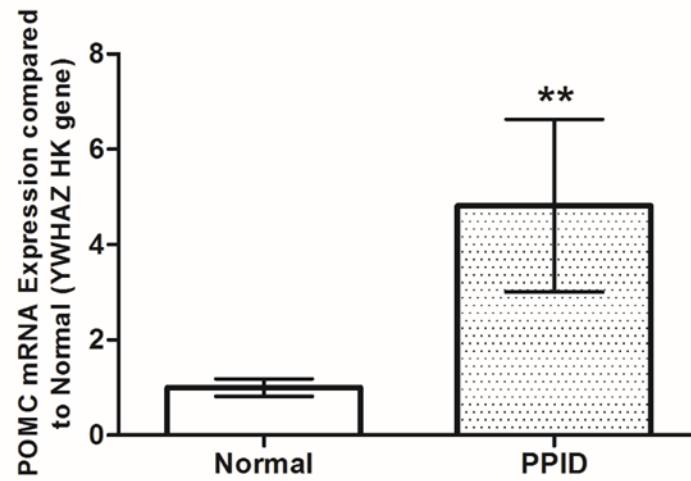


Figure 3.3C PC1 mRNA expression in the equine pituitary gland tissue from normal (n = 10) and PPID (n = 6) horses. Data are normalized to the YWHAZ house-keeping (HK) gene. Bars denote mean values (+/- SEM). *** = p < 0.001.

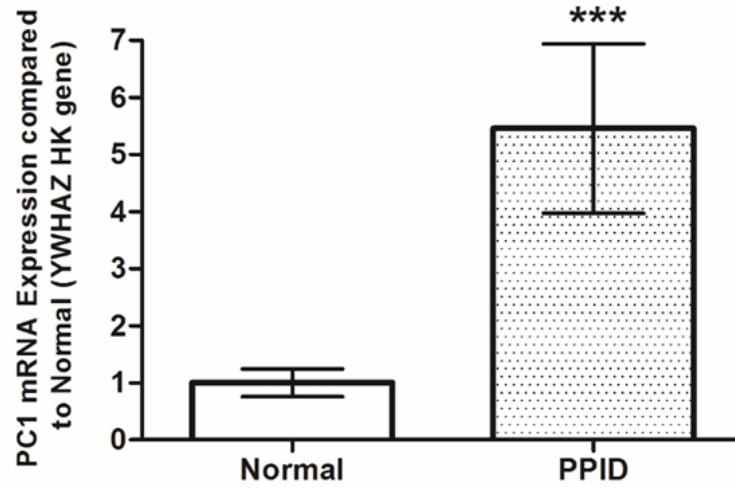


Figure 3.3D PC2 mRNA expression in the equine pituitary gland tissue from normal (n = 10) and PPID (n = 6) horses. Data are normalized to the YWHAZ house-keeping (HK) gene. Bars denote mean values (+/- SEM). ** = p < 0.01.

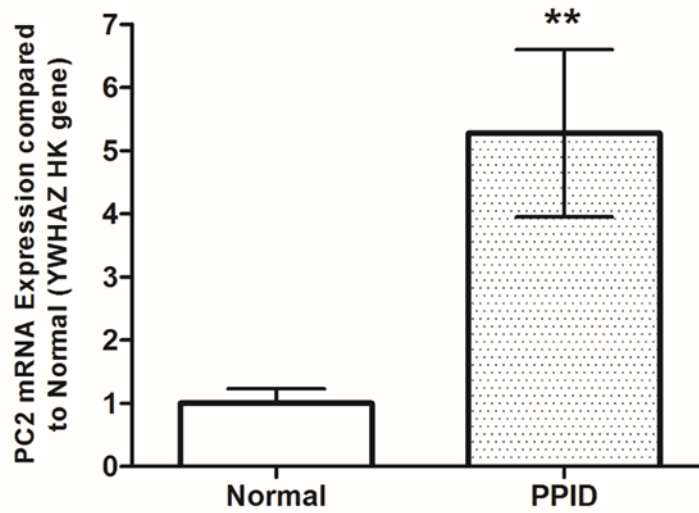


Figure 3.4A Plasma concentrations of POMC in the plasma of ventral cavernous sinus blood of normal (n = 6) and PPID (n = 6) horses. Bars denote mean values (\pm SEM).

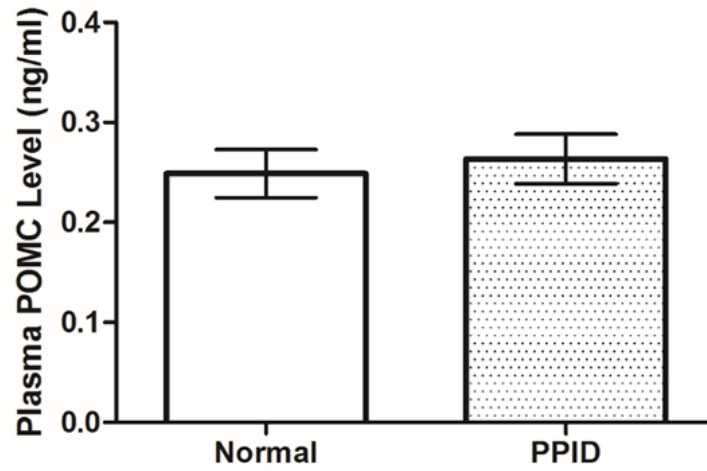


Figure 3.4B Plasma concentrations of ACTH in the plasma of ventral cavernous sinus blood of normal (n = 6) and PPID (n = 6) horses. Bars denote mean values (+/- SEM). *** = p < 0.001.

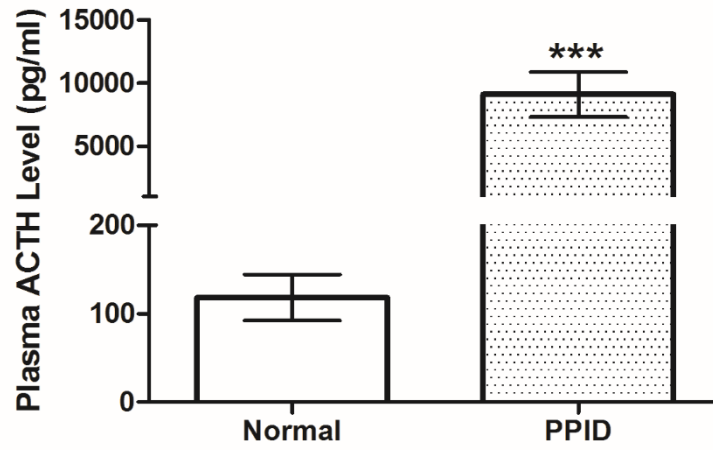


Figure 3.4C Plasma concentrations of α MSH in the plasma of ventral cavernous sinus blood of normal (n = 6) and PPID (n = 6) horses. Bars denote mean values (\pm SEM). *** = $p < 0.001$.

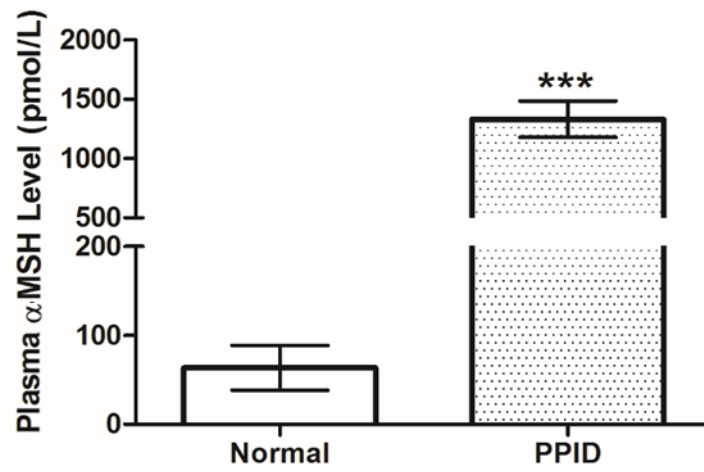
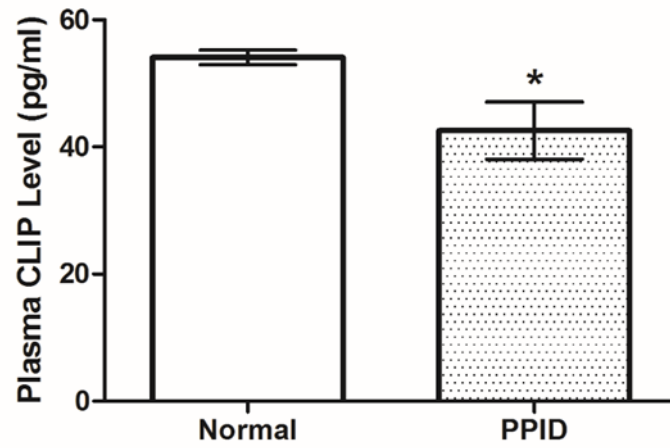


Figure 3.4D Plasma concentrations of CLIP in the plasma of ventral cavernous sinus blood of normal (n = 6) and PPID (n = 6) horses. Bars denote mean values (\pm SEM). * = $p < 0.05$.



3.5 DISCUSSION

This study partially confirmed the predicted equine POMC, PC1 and PC2 mRNA sequences, and found the expression of all three transcripts in the equine pituitary. Our sequencing data, although only partial, matched that of the predicted sequences of all three genes. Additionally, there were no key differences in the amino acid sequence of hormones encoded in POMC, or PC1 and PC2 between normal and PPID horses. These findings are interesting because there is strong evidence suggesting that a significant portion of the elevated endogenous ACTH in PPID horses is likely not bioavailable (Orth et al. 1982; Cordero et al. 2012). A mutation in the POMC gene was reported in humans, resulting in immunologically active, but biologically inactive ACTH (Samuels et al. 2013).

This mutation resulted in an ACTH analogue that could not bind to the M2R receptor on the adrenal gland. Our findings that the mRNA sequences of POMC, and the amino acid sequence of ACTH, did not differ between normal and PPID horses suggests that lack of ACTH bioactivity in horses is possibly not associated with a nucleotide polymorphism in the encoding gene. Combined with the clinical and laboratory evidence that treatment with a D2R-agonist normalizes endogenous ACTH levels, and the clinical signs of disease, our findings would suggest that the lack of ACTH bioactivity in PPID horses is more likely associated with post-translational modification of the nascent ACTH, downregulation of the M2R receptor on the adrenal gland, or some other yet unidentified mechanism. Multiple candidate genes were assessed for use as internal control genes in the equine pituitary gland. The results showing that both 18S rRNA and YWHAZ could be used as an internal control/house-keeping gene is

significant because this information has not previously been reported. The reduced variability in the expression of the latter gene resulted in its subsequent use in our study.

Our study found that POMC, PC1 and PC2 mRNA expression was elevated in the pituitary gland of PPID horses. Although only gene expression was studied here, this supports the mechanistic theory behind dopamine-deficient elevations in plasma ACTH concentrations extrapolated from murine studies (Saiardi et al. 1998). While both PC1 and PC2 mRNA expression increased in PPID horses, our results did not show the differential upregulation noted in D2R deficient mice, wherein PC1 increased in activity by 4 to 5 times, whereas that of PC2 increased by only 2 to 3 times (Saiardi et al. 1998). There are several possible explanations. Firstly, while mammalian hormone mechanisms are typically conserved, species specific differences do exist. Secondly, the murine studies that postulated a lack of dopamine, used type-2 dopamine receptor deficient D2R knock-out mice. These mice do not actually suffer from a true dopamine-deficiency. It is possible that differential receptor binding may have altered the relative upregulation of the prohormone convertase sub-types. Finally, our method of whole gland extraction precluded cellular localization of the PC enzymes. It is possible that differential upregulation occurred in multiple areas of the gland with the overall result that there was not a difference between PC1 and PC2. Had tissue been removed from specific pars intermedia or pars distalis regions, it is possible that differential upregulation in the face of PPID may have been revealed.

There were no differences in the concentration of POMC within the plasma of cerebral blood collected from the ventral cavernous sinus between PPID horses and control horses. This was not surprising because despite increased POMC mRNA expression, the protein would have been

cleaved into the downstream, smaller peptides, including ACTH, α -MSH and CLIP before release into the ventral cavernous sinus. Our findings concur with previously reported literature in that there were significant elevations in ACTH and α -MSH in PPID horses compared to control horses (Couëttil et al. 1996; Lee et al. 2010; Beech et al. 2013; McGowan et al. 2013). Interestingly, the increase in α -MSH was not mirrored by a concomitant rise in the concentration of CLIP. This was likely a function of the assay (which was not validated in this study) as initial analysis of α -MSH using an equine specific ELISA kit showed no elevation of hormone concentration in PPID animals (data not shown). Repeating the analysis using the radioimmunoassay as used by other investigators (McFarlane et al. 2006; Cordero et al. 2012; McGowan et al. 2013) resulted in the finding that a significant elevations in α -MSH occurred in PPID horses. It is possible that a CLIP-specific RIA would have demonstrated concomitant increases in this POMC-peptide, especially given the fact that α -MSH and CLIP are cleaved from ACTH.

In conclusion, the series of studies reported here supported the hypothesis that PC1 and PC2 in the equine pituitary gland is upregulated in PPID. This is associated with an abnormal abundance of POMC derived proteins being released into the blood of the ventral cavernous sinus, and then into the blood of the systemic circulation. We only determined partial sequences of POMC, PC1 and PC2. In addition, tissue expression of these proteins was not determined. Despite these limitations, our results conclude that upregulation of PC1 and PC2 occur in PPID horses which cleave a normal POMC polypeptide, resulting in elevated concentrations of POMC-derived peptides in the diseased state. Future research should focus on more in depth studies of the endocrine milieu during various stages of PPID.

Footnotes:

- ^a TRIzol. Invitrogen Inc. Canada.
- ^b TissueLyser, Qigen, Canada
- ^c Nanodrop. ND-2000c, Thermo Scientific Inc. Canada
- ^d iScript cDNA. Bio-Rad. Canada.
- ^e Primer-BlastTM: www.ncbi.nlm.nih.gov/tools/primer-blast/.
- ^f IDT Inc. Canada.
- ^g Taq DNA polymerase. Invitrogen Inc. Canada
- ^h Gel DocTM, EZ Imager, Bio-Rad, Canada.
- ⁱ QIAquick Gel extraction kit. Qiagen Inc. Canada
- ^j NCBI nucleotide blast. <https://blast.ncbi.nlm.nih.gov/Blast>.
- ^k <http://www.ebi.ac.uk>
- ^l CFX Connect, Bio-Rad, Canada
- ^m iQSYBR green supermix. Bio-Rad, Canada
- ⁿ Siemens ACTH kit, Siemens Canada, Oakville, ON, Canada
- ^o Immulite 1000 Chemiluminescent System, Siemens Canada, Oakville, ON, Canada
- ^p Bi-level ACTH control module, Siemens Canada Oakville, ON, Canada
- ^q POMC- MBS012413, MyBioSource Inc., San Diego, CA, USA
- ^r CLIP-MBS088236, MyBioSource Inc., San Diego, CA, USA
- ^s Euria – α -MSH, Euro Diagnostica AB, Malmö, Sweden
- ^t PRISM 5.0, GraphPad Software, Inc. La Jolla, CA USA
- ^u SPSS version 21, IBM Canada Ltd, Markham, ON, Canada

3.6 REFERENCES

Beech J, Boston RC, Lindborg S et al. Equine Cushing's disease: plasma immunoreactive proopiomelanocortin peptide and cortisol levels basally and in response to diagnostic tests. *J Am Vet Med Assoc* 2013; 27: 73-80.

Cordero M, Brorsen BW, McFarlane D. Circadian and circannual rhythms of cortisol, ACTH, and α -melanocyte-stimulating hormone in healthy horses. *Domest Anim Endocrinol* 2012; 43: 317-324.

Couëtil L, Paradis MR, Knoll J. Plasma adrenocorticotropin concentration in healthy horses and in horses with clinical signs of hyperadrenocorticism. *J Vet Intern Med* 1996; 10: 1-6.

Engler D, Pham T, Liu JP et al. Studies of the regulation of the hypothalamic-pituitary-adrenal axis in sheep with hypothalamic-pituitary disconnection. II. Evidence for in vivo ultradian hypersecretion of proopiomelanocortin peptides by the isolated anterior and intermediate pituitary. *J Endocrinol* 1990; 127: 1956-66.

Gehlert DR, Bishop JF, Schafer MP et al. Rat intermediate lobe in culture: Dopaminergic regulation of POMC biosynthesis and cell proliferation. *Peptides* 1988; 9(SUPPL. 1): 161-8.

Irvine CHG, Alexander SL. A novel technique for measuring hypothalamic and pituitary

hormone secretion rates from collection of pituitary venous effluent in the normal horse. *J Endocrinol* 1987; 113: 183-92.

Klein C, Rutllant J, Troedsson MH. Expression stability of putative reference genes in equine endometrial, testicular, and conceptus tissues. *BMC Res Notes* 2011; 4: 120.

Lee ZY, Zylstra R, Haritou SJA. The use of adrenocorticotrophic hormone as a potential biomarker of pituitary pars intermedia dysfunction in horses. *Vet J* 2010; 185: 58-61.

Livak KJ, Schmittgen TD. Analysis of Relative Gene Expression Data Using Real-Time Quantitative PCR and the $2^{-\Delta\Delta C_T}$ Method. *Methods* 2001; 25: 402-408.

McFarlane D, Beech J, Cribb A. Alpha-melanocyte stimulating hormone release in response to thyrotropin releasing hormone in healthy horses, horses with pituitary pars intermedia dysfunction and equine pars intermedia explants. *Domest Anim Endocrinol* 2006; 30: 276-88.

McFarlane D, Dybdal N, Donaldson MT et al. Nitration and increased alpha synuclein expression associated with dopaminergic neurodegeneration in equine pituitary pars intermedia dysfunction. *J Neuroendocrinol* 2005; 17: 73-80.

McGowan TW, Pinchbeck GP, McGowan CM. Prevalence, risk factors and clinical signs predictive for equine pituitary pars intermedia dysfunction in aged horses. *Equine Vet J* 2013; 45: 74-79.

Millington WR, Dybdal N, Dawson R et al. Equine Cushing's disease: differential regulation of beta-endorphin processing in tumors of the intermediate pituitary. *J Endocrinol* 1988; 123: 1598-604.

Orth D, Holscher M, Wilson M, et al. Equine Cushing's disease: plasma immunoreactive proopiomelanocortin peptide and cortisol levels basally and in response to diagnostic tests. *J Endocrinol* 1982; 110: 1430-1441.

Saiardi A, Borrelli E. Absence of dopaminergic control on melanotrophs leads to Cushing's-like syndrome in mice. *Mol Endocrinol* 1998; 12: 1133-1139.

Samuels ME, Gallo-Payet N, Pinard S et al. Bioinactive ACTH causing glucocorticoid deficiency. *J Clin Endocrinol Metab* 2013; 98: 736-742.

CHAPTER 4

INTRAAARTERIAL INJECTION OF IODINATED CONTRAST MEDIUM FOR CONTRAST ENHANCED COMPUTED TOMOGRAPHY OF THE EQUINE HEAD

CHAPTER 4

TRANSITION PAGE

Intraarterial injection of iodinated contrast medium for contrast enhanced computed tomography of the equine head.

This chapter presents the methodology for contrast-enhanced computed tomography using intraarterially delivered contrast material. This has the benefit of allowing the delineation of the margins of the pituitary gland and, additionally, being significantly more cost-effective than a large intravenous dose of contrast agent which suffers from volume depletion.

This work is important in that it allows a determination of pituitary gland size, which may be a helpful adjunct test in the ante-mortem diagnosis of pituitary pars intermedia dysfunction. This may allow earlier diagnosis of this condition to be made, resulting in earlier treatment and an improvement in the welfare of the aged horse.

Copyright statement: Chapter 4 has been published and is reproduced here with the permission of the copyright owner (Journal of Veterinary Radiology and Ultrasound – John Wiley and Sons, Inc.)

Full citation: Carmalt JL and Montgomery J. Intraarterial injection of iodinated contrast medium for contrast enhanced computed tomography of the equine head. *Vet Radiol Ultrasound*. 2015; 56(4): 384-390. doi: 10.1111/vru.12252

Author contributions: Carmalt conceptualized the experiment, performed the surgical approach to the carotid arteries and the ultrasound guided intra-arterial contrast agent delivery. He also read the CT images, performed measurements of the pituitary glands and regions of interest and statistical interpretation. Montgomery provided the expertise as to the time-of-flight technique. Carmalt wrote the paper with editorial input from Montgomery.

4.1 ABSTRACT

Objectives: To determine whether low-volume intraarterial administration of contrast medium would result in an equivalent image quality and tissue attenuation versus high-volume intravenous bolus administration for enhanced computed tomography (CT) of the equine head.

Materials and Methods: A prospective cross-over experimental design was used in 6 horses. After anesthetic induction, the right carotid artery was exposed surgically and catheterized. Four CT scans of the cranium were performed for each horse: baseline, immediately following intraarterial contrast injection, 5-minutes post injection (return to baseline) and after intravenous contrast administration. Soft tissue attenuation in pre-determined regions of interest (ROI); and length, width and height measurements of the pituitary gland were recorded at each time point. Horses were euthanased and pituitary gland measurements were repeated post-mortem.

Results: Margins of the pituitary gland could not be accurately delineated without contrast enhancement. Intraarterial and intravenous administration of contrast medium resulted in significantly greater soft tissue enhancement of some brain ROI and the pituitary gland versus baseline values. Pituitary gland measurements made on post-contrast CT images did not differ from those obtained during postmortem examination.

Conclusions: Low-dose intraarterial administration of contrast material in the equine head resulted in comparable soft tissue enhancement versus high-volume intravenous administration.

4.2 INTRODUCTION

Computed tomography (CT) is a widely used advanced imaging modality for diagnosis of suspected cranial lesions and surgical planning in the equine head (Puchalski et al. 2010). While superior to CT for evaluation of soft tissues, disadvantages of magnetic resonance imaging (MRI) for the equine head include less availability, longer anesthesia times, and greater expense (Holmes 2013). While more available, disadvantages of radiographic cerebral angiography for the equine head include high contrast medium dosages and costs. There are few publications describing the use of contrast agent administered via an intravenous (IV) injection for enhanced computed tomography of the equine head and dosages vary widely. One report examined the brain after traumatic head injury and another assessed the long-term (6 months) effect of pergolide treatment on pituitary gland size (Lacombe et al. 2010; Pease et al. 2011). Both of these report high-volume IV injection of iodinated contrast medium: Pease et al. – 250 mL of 370 mgI/mL; Lacombe et al. – approximately 300 mL of 350 mgI/mL. A third report discussed the use of contrast-enhanced CT as a potentially useful tool in the assessment of the equine head, but did not report the dose to administer, or discuss timing of the scan required to acquire contrast-enhanced images of the head (Kinns and Pease 2009). A previous cadaver study used contrast-enhanced CT to describe effects of CT slice thickness on equine pituitary gland measurements and reported a dosage of 60 mL administered by bolus injection IV immediately ante-mortem (McKlveen et al. 2003) and a single abstract reported the use of intraarterial (IA) contrast administration for CT the equine head (Bergman et al. 2012).

Disadvantages of IV contrast administration center around the large volume of contrast medium required in a horse. This leads to a high cost of contrast material, and an extended duration of the injection time. With a long injection time there is marked dilution of the contrast medium within the vascular space and decreased contrast enhancement. When administered IA and targeted to a specific region such as the head, a lower volume of contrast medium can be used, as has been demonstrated in the equine distal limb (Puchalski et al. 2007). This would help reduce the cost associated with contrast medium administration, and may provide greater contrast resolution when compared to the previously reported high-volume IV contrast techniques. An IA contrast injection technique may also be helpful for comparing characteristics of intracranial structures during arterial and venous phases.

The objectives of the current study were to determine whether a low-volume IA bolus of contrast medium would result in equivalent image quality and tissue attenuation on CT examination versus a high-volume IV bolus technique; and whether contrast administration allowed greater delineation of the hypophyseal margins such that the accuracy of size measurements of this intracranial structure would be improved above those obtained without the use of contrast material. The hypothesis was that low-volume IA contrast administration would prove to be equal, both in terms of image quality and contrast-enhancement; and would result in comparable hypophyseal margin delineation with the high-volume IV technique.

4.3 MATERIALS AND METHODS

This work was approved by the University of Saskatchewan Animal Research Ethics Board and adhered to the Canadian Council on Animal Care guidelines for humane animal use.

Six horses, weighing between 475 kgs and 550 kgs were recruited. Included horses were either surrendered by their owner or were destined for slaughter. Each horse had the jugular furrows clipped of hair prior to IV jugular catheterization of the right jugular vein. Horses were then pre-medicated using 1.1 mg/kg xylazine^a and anesthesia was induced with 2.2 mg/kg ketamine^b both administered IV. Anesthesia was maintained with IV “triple-drip” (xylazine, ketamine and guaiphenesin combination) with the addition of intranasal oxygen for the duration of the procedure.

Horses were positioned in left lateral recumbency and a 10 cm surgical incision was made in the right jugular furrow, immediately superficial to the jugular vein. The right common carotid artery was isolated from the vagosympathetic trunk and catheterized with a 14 G 3.5” catheter^c. A Penrose drain was placed around the isolated artery to facilitate later identification and the artery allowed to return into the incision. A sterile towel was placed over the incision and the horse moved to the computed tomography suite. In Horse 6, a second common carotid artery catheterization was performed percutaneously using ultrasound guidance to determine whether surgical intervention was necessary to perform intraarterial contrast administration.

The horses were placed in left lateral recumbency on the CT table and positioned at the start of the IA scan with the table advanced as far forward as possible (i.e., such that the direction of the scan acquisition would follow the direction of blood flow). After the mean arterial pressure (MAP) of the horse was stabilized at 70 mmHg, a pre-contrast CT of the cranium was performed using a standard protocol^d. Technical factors included a helical acquisition with pitch of 0.94, slice width 1 mm, tube rotation time of 0.75 seconds, 135 kVp, 380 mA, and 512 x 512 image matrix. All scans were reconstructed with a soft tissue and bone algorithm. The rostral limit of the scan was immediately rostral to the cribriform plate extending as far caudal on the neck as the size of the horse would permit in terms of entry into the CT gantry, generally to the level of the second cervical vertebrae. This was followed by the administration of 44 mL of 240 mgI/mL Iohexol^e delivered into the carotid artery with a pressure injector^f at a rate of 4 mL/s and pressure limited to a maximum of 325 psi. A scanning protocol to include arterial and venous phases of contrast enhancement was performed. The initial scan was started 5 seconds after the initiation of the injection such that 20 mL of the total 44 mL volume of the injection had been infused with continual injection throughout the arterial phase scan. The length of the scan varied between horses as the size of the horses and subsequent area included in the scan differed between animals.

After the IA post-contrast CT scan was performed, there was a delay of 5 minutes prior to an additional scan of the same region placing ROI in predetermined locations to verify that tissues had returned to their pre-contrast (baseline) administration attenuation levels, as determined in the pre-contrast CT.

Once confirmed, the high-volume IV angiographic scan was performed using manual injection of 240 mL Iohexol 350 mgI/mL (due to the large volume being greater than the capacity of the pressure injector) via the jugular vein catheter. The start time for the scan after the IV injection was 1 minute, allowing for delivery of the contrast agent to the cerebrum.

Objective assessment of soft tissue contrast enhancement was performed by measuring the Hounsfield units (HU) within an ROI at multiple locations in the images which were standardized for all horses in an axial slice in a soft tissue window at the level of the middle of the pituitary gland: 1) the center of the pituitary gland, 2) right cerebrum, 3) left cerebrum, 4) right temporalis muscle, 5) left temporalis muscle, 6) right digastricus muscle, 7) left digastricus muscle, 8) right jugular vein, and 9) left jugular vein. The sizes of the ROI were standardized within each patient and, in positioning the ROI every effort was made to locate them at a corresponding position between patients. Subjective assessment of image quality was also recorded. The region of the hypophysis was identified and the margins delineated, if possible. The images were viewed in a window width of 350, and window level of 35. The length (measured in a sagittal plane reconstruction), width and height of the gland was measured and recorded in the pre-contrast, as well as in both the IV and IA injection post-contrast sequences.

After the completion of the diagnostic procedure the horses were euthanised using an IV overdose of barbiturate. Heads were disarticulated and the crania opened. The brain was removed leaving the hypophysis *in-situ*. This was carefully elevated from the underlying

basisphenoid bone and the length, width and height were measured using calipers. All data were subsequently entered into a Windows-based spreadsheet program^g and statistics performed using a commercial statistical software package^h.

Linear regression generalized estimating equations assuming a normal distribution and controlling for repeated observations on individual horses were used to examine the effect of potential risk factors on soft tissue attenuation (HU), before and after each of the contrast administration techniques (IA and IV). All potential risk factors (age, sex, location of ROI and method of contrast administration (baseline, IA, IV)) were initially screened using unconditional analysis and variables where the p-value of < 0.2 were submitted for consideration in building the final model (Dohoo et al. 2010). All final models were built using manual backwards elimination. Variables that were not significant were assessed as potential confounders. Risk factors were considered confounders if adding or removing the factor from the model changed the regression coefficient for another risk factor by more than 10% (Dohoo et al. 2010). Where 2 or more variables were significant, biologically plausible 2-way interactions were assessed with significant interactions retained in the final model ($p < 0.05$). All possible pairwise comparisons were examined for significant categorical interactions using a least significant difference adjustment for multiple comparisons.

Comparisons of the measurements taken of the pituitary gland obtained at baseline, intraarterial or intravenous contrast enhancement were performed using an analysis of

variance with those obtained at post-mortem used as the definitive measurements. The level of significance was set at $p < 0.05$.

4.4 RESULTS

There were 3 mares and 3 geldings. The mean age of horses was 21 years (SD +/- 5.97 years, range 14 to 30 years). No significant alterations in MAP or anesthetic depth accompanied either method of contrast agent administration. There was no seizure-like activity noted during any of the procedures.

Unconditional analyses of factors potentially affecting soft tissue attenuation are presented in Table 4.1. The final multivariable model is presented in Table 4.2. Univariable analysis indicated that sex, ROI location and the method of contrast administration affected soft tissue enhancement. Geldings had more soft tissue enhancement than mares ($p < 0.001$). The multivariable model included sex, location of ROI and method of contrast administration as well as interaction terms between ROI and method of contrast administration ($p < 0.001$) and between sex and ROI ($p < 0.001$). There was no interaction between method of contrast administration and sex, nor a 3-way interaction between the significant terms. The left jugular vein had significantly greater contrast enhancement with the IV (predicted mean HU 60.92 +/- SD 10.06) than the IA administration (32.85 +/- 5.92, $p < 0.001$) or baseline values (34.97 +/- 6.92, $p < 0.001$).

Table 4.1 Unconditional analysis of potential factors on soft tissue attenuation measured in Hounsfield units

Potential Factor	β^a	95% Confidence Interval		p-value
		Lower	Upper	
Age (years)	0.32	- 0.21	0.85	0.23
Sex (gelding versus mare)	8.09	4.72	11.45	< 0.001
ROI (Overall) ^b				< 0.001
ROI = Left jugular vein	- 12.06	- 20.17	- 5.04	0.001
ROI = Right jugular vein	- 7.86	- 17.12	1.41	0.10
ROI = Left digastricus muscle	1.10	- 6.09	8.30	0.76
ROI = Right digastricus muscle	2.45	- 5.93	10.78	0.57
ROI = Left temporalis muscle	- 16.41	- 28.06	- 4.75	0.006
ROI = Right temporalis muscle	- 5.85	- 15.25	4.27	0.24
ROI = Left cerebrum	- 24.79	- 32.52	- 17.06	< 0.001
ROI = Right cerebrum	- 26.73	- 35.79	- 17.68	< 0.001
ROI = Pituitary gland		Reference Category		
MOCA ^c (Overall)				< 0.001
MOCA = Baseline versus IA	- 7.11	- 11.25	- 2.97	0.001
MOCA = Baseline versus IV	- 10.66	- 14.33	- 6.99	< 0.001
MOCA = IA versus IV	- 3.55	-7.71	0.61	0.09

^a β = Regression coefficient

^b ROI = Region of interest

^c MOCA = Method of contrast administration

Table 4.2 Final multivariable model of factors affecting soft tissue attenuation measured in Hounsfield units.

Factor	β^a	95% Confidence Interval		p-value
		Lower	Upper	
Sex = M	11.65	1.57	21.73	0.02
Sex = F		Reference Category		
ROI ^b = Left jugular vein	- 0.70	- 14.17	12.78	0.92
ROI = Right jugular vein	- 5.50	- 17.71	6.71	0.38
ROI = Left digastricus muscle	18.64	6.14	31.13	0.003
ROI = Right digastricus muscle	14.60	- 2.14	31.34	0.09
ROI = Left Temporalis muscle	1.89	- 8.56	12.34	0.72
ROI = Right Temporalis muscle	0.34	- 10.45	11.14	0.95
ROI = Left cerebrum	- 13.58	- 24.29	- 2.87	0.01
ROI = Right cerebrum	- 14.28	- 27.27	- 1.30	0.03
ROI = Pituitary gland		Reference Category		
MOCA ^c = IV	11.47	6.06	16.89	< 0.001
MOCA = IA	26.02	5.52	46.51	0.01
MOCA = Baseline		Reference Category		
MOCA * ROI ^d				< 0.001
Sex * ROI ^d				< 0.001

^a β = Regression coefficient

^b ROI = Region of interest

^c MOCA = Method of contrast administration

^d Interaction term within the final model

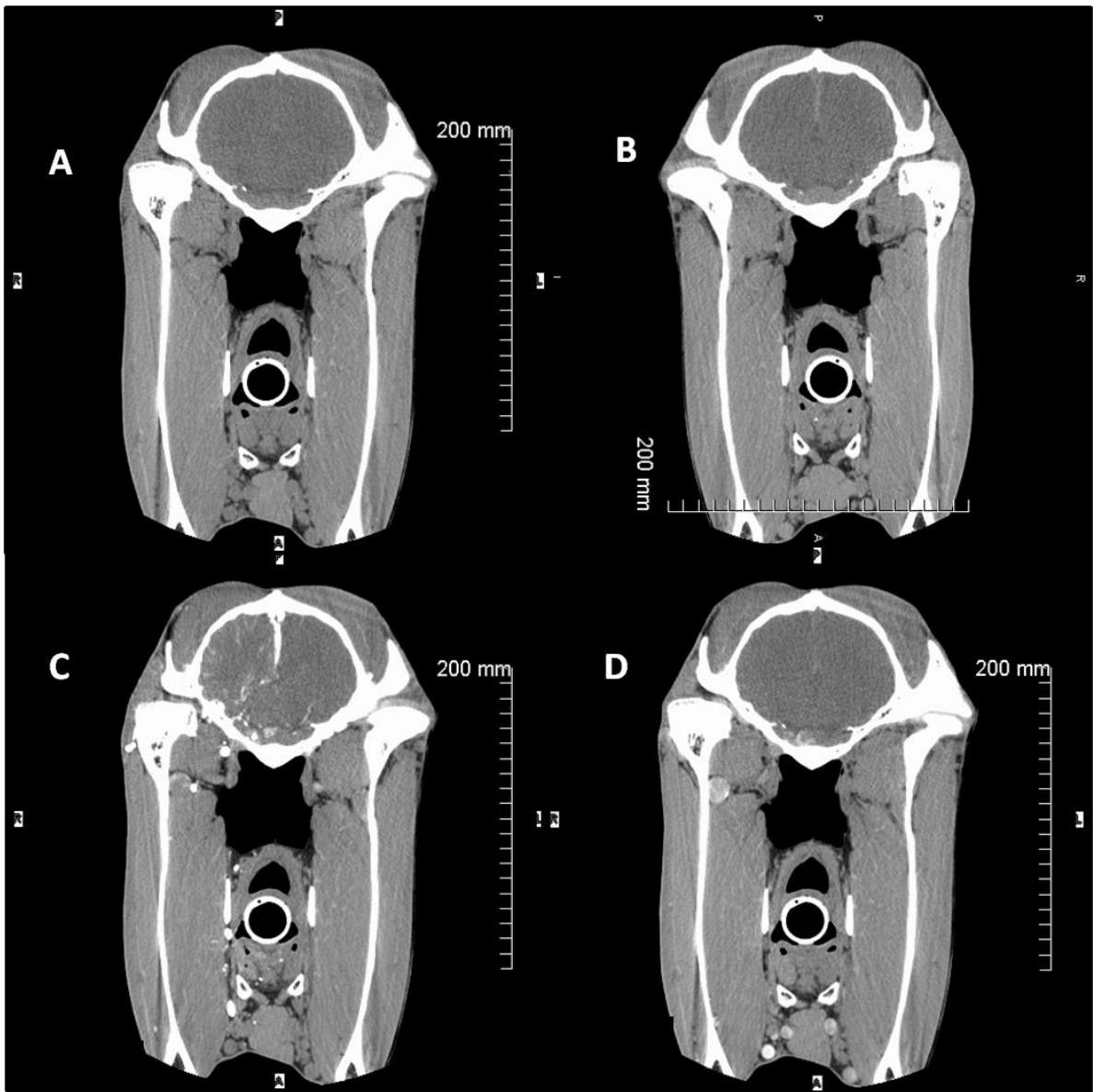
The right jugular vein contrast enhancement was greatly increased with both IV (61.46 +/- 12.68 HU) and IA administration (50.38 +/- 23.24 HU) over baseline values (28.60 +/- 6.20 HU), but only significantly greater with the IV administration ($p < 0.001$). Both administration methods resulted in significant contrast enhancement of the right digastric muscle (IV = 57.59 +/- 3.44 HU; IA = 56.82 +/- 3.44 HU; baseline = 50.55 +/- 4.56 HU, $p < 0.001$) and the pituitary gland (IV = 57.59 +/- 3.44 HU; IA = 56.82 +/- 3.44 HU; baseline = 50.55 +/- 4.56 HU, $p = 0.008$), but no difference between the IV or IA methods ($p = 0.62$ and 0.07 , respectively).

There was a significant difference between male and female horses (with the male horses having the greater contrast enhancement) at the left (male = 50.89 +/- 2.9 HU; female = 35.46 +/- 3.46 HU) and right (male = 51.78 +/- 11.6 HU; female = 36.58 +/- 6.14 HU) temporalis muscles, as well as the right cerebrum (male = 33.25 +/- 8.90 HU; female = 22.08 +/- 6.76 HU; $p < 0.001$, 0.023 and 0.04 respectively)

The lateral, rostral and caudal margins of the pituitary gland could not be accurately delineated without contrast enhancement (Figure 4.1). Following contrast administration (IV or IA) measurements were not significantly different from those obtained during postmortem examination ($p > 0.13$). There was no significant difference in the measurements obtained between methods of contrast administration.

Figure 4.1 Axial CT slices of the same horse at the same level of the pituitary gland.

A) Pre-contrast administration, B) High-volume IV injection, C) Low-volume IA arterial phase, D) Low-volume IA venous phase.



4.5 DISCUSSION

Results of this study show that the low-volume IA and high-volume IV techniques for contrast-enhanced computed tomography of the equine cerebrum are comparable. Initially the IA injection was to be 30 mL of 350 mgI/mL iohexol. This dose was chosen as it was within the range of reported volumes used in human cranial CT angiography (Takeyama et al. 2008; Takeyama et al. 2012; Li et al. 2013). During the initial scan we discovered that the use of the power injector and 350 mgI/mL contrast medium created significant artifact due to the tight bolus of contrast medium with very little dilution in the blood pool. This created streak and blooming artifacts. Streak artifacts occur when large quantities of intravascular contrast medium are present, particularly when, as in the case here, the vessel into which the contrast is injected is in the imaging field. Blooming artifact is the blurring of the vascular margins and apparent increase in the size of the vessel diameter due to non-diluted contrast medium within the vessel (Pollard and Puchalski 2013). The protocol was therefore modified to dilute the 350 mgI/mL contrast medium to 240 mgI/mL with the addition of sterile saline creating a total volume of 44 mL which was injected IA. Interestingly, a recent abstract reports the use of 180 mL iodinated contrast medium, in each of the carotid arteries delivered simultaneously for contrast-enhanced CT of the head in horses with disease of the skull or brain (Bergman et al. 2012). No mention of artifact was documented.

The IA contrast administration was followed, following a wash-out period, by an intravenous injection of 240 mL iohexol (350 mgI/mL). From an experimental model

standpoint, the project would have been more robust if a 2 x 2 Latin square design had been followed. As such, the effect of sequence of treatment (IA followed by IV) cannot be separated from the effect of treatment (i.e., the difference between treatments). The order of the different methods of contrast delivery were not randomized between horses as the low-volume of contrast medium was expected to wash out rapidly from the soft tissues and the authors desired to minimize the duration of the anesthetic procedure. Given that in humans, the half-life for non-ionic iodinated contrast medium excretion has been reported to be 110 minutes (Krause et al. 1994) we expected that the time required for the soft tissues to return to their baseline, pre-contrast administration attenuation values, would have been significantly increased if the high-volume intravenous contrast injection had been administered first. Further work is required to determine whether our concerns were justified.

Subjectively, the IA injection of contrast medium resulted in impressive ipsilateral contrast enhancement within the cranium. Statistically, however, when controlling for horse and sex, measurements of soft tissue attenuation were not greater than baseline. There was also no significant difference ($p = 0.34$, data not shown) between right (ipsilateral) and left (contralateral) cerebrae. This was also the fact with the high-volume IV contrast administration. Both methods of contrast administration allowed excellent visibility and delineation of the margins of the pituitary gland, especially in the venous phase of the IA injection allowing for accurate measurements of the gland, confirming a previous report (Pease et al. 2011). The lack of ipsilateral contrast enhancement with IA contrast administration was likely due to a lack of statistical power. However, in cases

where neurological symptoms exist that are not clearly defined, bilateral, concurrent IA contrast administration may be necessary, as has been previously reported (Bergman et al. 2012).

The effect of sex was unexpected and it is difficult for the authors to draw any definitive conclusions from these findings. It is possible that the males had an increased temporalis muscle mass which, in turn, required greater vascularization, but this is pure conjecture. We have no explanation for the significantly increased soft tissue attenuation of the right cerebrum, which was noted in the baseline measurements as well as after contrast administration. It is possible that pathological differences in this region were missed due to the fact that no histological examination was made of this region of the brain. However, it is more likely that low numbers of each sex are playing a role in these findings.

We were able to successfully perform low-dose IA contrast-enhanced CT of the equine head. The cut-down method was chosen in this study so that complete insertion of the catheter was achieved in every case. This allowed standardization of the IA method of contrast administration.

In clinical practice, the ultrasound-guided percutaneous route would be used. Our experience generated from a single horse, did not show a difference in the contrast enhancement of the soft tissue structures achieved with this, compared to the cut down

method of accessing the carotid artery. Additional prospective research assessing potential complications of percutaneous catheterization of the carotid artery is needed.

Additional research is needed to optimize the scan parameters for different sized horses which could alter the length of the scan time and, therefore, the timing of the arterial and venous phases in the head, but that was beyond the focus and financial constraints of the current study. Clinical applications of this technique include any CT study in which contrast enhancement of intra-cranial structures or CT angiography is necessary. As an example, evaluation of the pituitary gland as an adjunct diagnostic test for pituitary pars intermedia dysfunction, to assess the impact of treatment (Pease et al. 2011), or to guide local therapy using low, rather than high-volume contrast enhancement may allow repeated scans in a single session without being cost-prohibitive.

Horses in this study were not recovered from anesthesia. For this reason, the effect of IA administration of contrast material could not be determined. The use of ionic iodinated contrast material in the horse has been reported to cause reactions directly attributable to the material in 9% of cases (Pollard and Puchalski 2011). These authors report that no horse suffered severe systemic shock or had an anaphylactoid response as a result of these agents which were delivered into the distal extremities in all cases. The current authors are unaware of any reports of complications associated with intraarterial administration of non-ionic iodinated contrast agents (as used in this study) in the horse and this method of delivery is a commonly employed technique in the surgical treatment of equine guttural pouch mycosis (Freeman and Hardy 2012; Colles and Cook 1983).

In conclusion, we demonstrated that an IA injection can be used with a much lower volume of contrast medium with equal contrast enhancement of the cerebrum as an IV contrast medium injection of a much higher volume. Neither method significantly increased the soft tissue attenuation of the musculature of the equine head. Accurate measurement of the size of the equine pituitary gland can be performed using contrast enhancement with either delivery method.

Footnotes:

^a Xylamax, Bimeda, Cambridge, ON, Canada

^b Vetalar, Bioniche, Belleville, ON, Canada

^c Angiocath, Becton Dickinson, Mississauga, ON, Canada

^d Toshiba Aquilion 16, Toshiba Medical Systems, Markham, Ontario

^e Omnipaque, GE Healthcare Canada, Inc., Mississauga, Ontario

^f Medrad Stellant Sx, Bayer HealthCare, Medrad, Inc. Indianola, PA

^g Microsoft Excel, Microsoft Canada Inc, Mississauga, ON, Canada

^h SPSS, IBM Canada Ltd, Markham, ON, Canada

4.6 REFERENCES

Bergman HJ, Puchalski S, Saunders J. Intracarotid contrast-enhanced computed tomography of the equine head. Proceedings of the 16th IVRA Meeting & EVDI Annual Meeting 2012; 97.

Colles CM and Cook WR. Carotid and cerebral angiography in the horse. Vet Rec 1983; 113: 483-489.

Dohoo I, Martin W, Stryhn H. Model-building strategies. In: Veterinary Epidemiologic Research, 2nd Edn., 2012, VER Inc. Charlottetown, Prince Edward Island, Canada pp 365-394.

Freeman DE and Hardy J. Guttural Pouch. Equine Surgery 4th Edn. St. Louis, Elsevier Saunders, 2012: 623-642.

Holmes SP. Equine skull magnetic resonance imaging: The where, when and why ? Equine Vet Educ 2014; 26: 605-609.

Kinns J, Pease AP. Computed tomography in the evaluation of the equine head. Equine vet. Educ 2009; 29: 291-294.

Krause W, Schuhmann-Giampieri G, Staks T et al. Dose proportionality of iopromide pharmacokinetics and tolerability after IV injection in healthy volunteers. *Eur J Clin Pharmacol* 1994; 46: 339-343.

Lacombe VA, Sogaro-Robinson C, Reed SM. Diagnostic utility of computed tomography imaging in equine intracranial conditions. *Equine Vet J* 2010; 42: 393-399.

Li Q, Lv F, Yao G, Li Y, Xie P. 64-section multidetector CT angiography for evaluation of intracranial aneurysms: comparison with 3D rotational angiography. *Acta Radiol* 2014; 55: 840-846.

McKlveen TL, Jones JC, Sponenberg DP et al. Assessment of the accuracy of computed tomography for measurement of normal equine pituitary glands. *Am J Vet Res* 2003; 64: 1387-1394.

Pease AP, Schott II HC, Howey EB et al. Computed tomographic findings in the pituitary gland and brain of horses with pituitary pars intermedia dysfunction. *J Vet Intern Med* 2011; 25: 1144-1151.

Pollard RE, Puchalski, SM. Reaction to intraarterial ionic iodinated contrast medium administration in anesthetized horses. *Vet Radiol Ultrasound* 2011; 52: 441-443.

Pollard R, Puchalski SM. CT contrast Media and Applications. In Schwarz T and Saunders J, eds. *Veterinary Computed Tomography*. Wiley-Blackwell (Chichester, UK) 2013; pp 57-65.

CHAPTER 5

EFFECTS OF ANESTHESIA WITH ISOFLURANE ON PLASMA
CONCENTRATIONS OF ADRENOCORTICOTROPHIC HORMONE IN SAMPLES
OBTAINED FROM THE CAVERNOUS SINUS AND JUGULAR VEIN OF HORSES

CHAPTER 5

TRANSITION PAGE

Effects of anesthesia with isoflurane on plasma concentrations of adrenocorticotrophic hormone in samples obtained from the cavernous sinus and jugular vein of horses.

This chapter presents the effect of general anesthesia on concentrations and pulsatility of ACTH in ventral cavernous sinus (pituitary effluent) blood. Determining this is an important step in the application of the surgical technique to treatment of PPID.

This work is important as it allows for the objective, real-time measurement of any change in endogenous ACTH production brought about by the manipulation of the pituitary gland. These changes may be used in surgery to determine the degree of selective surgical ablation of the pituitary gland in PPID horses.

This work represents four important facets of research. Firstly, it is a proof of principle; secondly, it has intrinsic heuristic value; thirdly, the results are in contrast with those published elsewhere and finally, this technique may have application as a measure of stress in hospitalized and anesthetized equine patients.

Copyright statement: Chapter 5 has been published and is reproduced here with the permission of the copyright owner (American Journal of Veterinary Research – American Veterinary Medical Association)

Full citation: Carmalt JL, Schott II HC, van der Kolk J and Duke T. Effects of anesthesia with isoflurane on plasma concentrations of adrenocorticotrophic hormone in samples obtained from the cavernous sinus and jugular vein of horses. *Am J Vet Res* 2016; 77: 730-737.

Author contributions: Carmalt performed the catheterizations, blood collections and sample preparations. Duke performed the anesthesia. Schott and van der Kolk provided support during the experimental design phase. Van der Kolk performed the auto-deconvolution statistics while Carmalt performed all other statistical interpretation. Carmalt wrote the paper and all other authors contributed to the editing of the manuscript.

5.1 ABSTRACT

Objective: To determine the effect of general anesthesia on concentrations and pulsatility of adrenocorticotrophic hormone (ACTH) in cavernous sinus and peripheral plasma.

Materials and Methods: Cavernous sinus blood was sampled via an indwelling catheter every 5 minutes for 1 hour, while peripheral blood was sampled at 0, 30 and 60 minutes. The next day, horses were placed under general anesthesia and 1 hour after induction, the same blood sampling protocol was repeated. ACTH concentrations were quantified using a commercially available sandwich assay. Generalized estimating equations controlling for individual horse, and an expressly automated deconvolution algorithm, were used to determine the effect of general anesthesia on plasma ACTH concentrations and pulsatility, respectively.

Results: General anesthesia significantly reduced ACTH concentration in the cavernous sinus blood, as well as the number of secretion peaks.

Conclusions: An overall reduction in mean plasma concentration of equine ACTH under anesthesia indicates that if partial-ablation of the pituitary gland *in-situ* is successful for treatment of pituitary pars intermedia dysfunction, the expected reduction in cavernous sinus ACTH concentration following ablation would have to be interpreted in light of the effects of general anesthesia.

5.2 INTRODUCTION

Adrenocorticotrophic hormone (ACTH) is produced both in the pars distalis and pars intermedia of the equine pituitary gland. The hormone stimulates the adrenal gland to synthesize and release cortisol into the blood which then acts on the hypothalamus and pituitary gland in a negative feedback manner to manage overall circulating concentrations of this stress hormone to maintain homeostasis under different conditions (Alexander et al. 1996).

Pituitary pars intermedia dysfunction (PPID) or equine Cushing's disease is a common disease of older horses. There is mounting evidence that PPID develops as a consequence of the progressive loss of hypothalamic dopaminergic innervation to the pars intermedia, leading to hyperplasia and hypertrophy of the pars intermedia melanotrophs (Millington et al. 1998; McFarlane 2011). Pars intermedia melanotrophs produce proopiomelanocortin (POMC), a 241 amino acid propeptide that is subsequently cleaved into smaller peptides by prohormone convertase enzymes. These include ACTH₁₋₃₉ (138 to 176 amino acid segment of POMC) as well as other POMC-derived peptides. Dopamine released by hypothalamic neurons inhibits POMC production in normal horses and loss of this regulatory control leads to increased production and release of POMC-derived peptides, including ACTH, in PPID-affected equids. Consequently, detection of elevated ACTH concentrations in peripheral blood is a commonly used test to support a diagnosis of PPID (van der Kolk et al. 1995; Couëttil et al. 1996; Lee et al. 2010; McGowan et al. 2013).

Both pars distalis hormones and POMC-derived peptides from the pars intermedia are secreted into the secondary plexus of the hypothalamic hypophyseal portal system and subsequently flow into the cavernous sinus that lines the hypophyseal fossa of the sella turcica and surrounds the pituitary gland. This cavernous sinus blood contains high concentrations of hormones secreted by the pars distalis and pars intermedia. Fortunately, access to the cavernous sinus of the horse can be accomplished by insertion of a flexible catheter into a superficial facial vein, as first described by Irvine and Alexander (1987). Since that initial report, this technique has been used in numerous studies both to sample cavernous sinus blood to more directly assess hormone release from the pituitary gland (Irvine and Hunn 1984; Irvine and Alexander 1987; Alexander et al. 1996), as well as to measure cavernous blood temperature as an estimate of brain temperature in exercising horses (McConaghy et al. 1995). Using a discrete peak-detection method on ACTH concentrations measured in frequently collected equine cavernous sinus blood samples, ACTH has been found to be released in a pulsatile fashion from the pituitary gland with 10.2 (+/- SD 1.4) ACTH concentration peaks, or pulses, per hour reported in Standardbred horses (Alexander et al. 1994). However, as cavernous sinus blood mixes with venous blood from other parts of the head while draining into the jugular vein, hormone concentrations decrease and pulsatility of hormone release may no longer be apparent in peripheral blood. Thus, measurement of ACTH in cavernous sinus blood provides a more direct assessment of pars distalis and pars intermedia activity, and would also provide a more accurate assessment of changes in ACTH concentration that may be attributable to treatments for PPID.

Anesthesia in the horse is inherently physiologically stressful which can result in elevations of plasma ACTH and cortisol concentrations, also known as the stress response (Taylor 1989). Halothane anesthesia, without attendant surgery, resulted in a dose-dependent stress response in horses that was attributed to cardiopulmonary depression (Taylor 1989; Luna 1995). Induction of general anesthesia with xylazine and ketamine, followed by maintenance with either halothane or isoflurane, also produced an increase in cortisol concentration that may have also been a consequence of cardiopulmonary depression (Taylor 1991). Horses maintained with isoflurane were more hypercapnic compared to horses anesthetized with halothane, yet horses in both groups were hypotensive.

Over the past few decades, treatment of ACTH-dependent Cushing's syndrome in people has changed from medical treatment to surgical intervention in the form of ablation of hypophyseal adenomas, as the current treatment of choice (Biller et al. 2008). Further, intra-operative ACTH measurements from both internal jugular veins provide information about completeness of partial-ablation and, consequently, support intraoperative decision making in patients with Cushing's syndrome undergoing transsphenoidal surgery (Bons et al. 2014). As our research team is considering techniques to ablate the pars intermedia as an alternative to medical treatment of PPID (Sakes et al. 2015), further knowledge about factors that may affect cavernous sinus ACTH concentrations is needed. Specifically, pituitary gland manipulation in PPID horses will likely be performed under general anesthesia. Consequently, the effect of anesthesia on both the concentration and the pulsatility of ACTH release in both normal

and PPID-affected equids needs to be determined. This will allow for the assessment of the effects of ablation to be evaluated independent of the effects of anesthesia.

The objective of the study reported here was to determine if maintenance of general anesthesia with isoflurane produces alterations in ACTH concentration or pulsatility in cavernous sinus blood. The null hypothesis stated that isoflurane anesthesia would not result in alterations of ACTH concentration or pulsatility in cavernous sinus blood.

5.3 MATERIALS AND METHODS

Six horses (5 mares and 1 gelding; 4 Quarter horses, 1 Thoroughbred and 1 Arabian) with mean bodyweight of 470 kg (+/- SD 32; range 427 to 500 kg) were maintained in box stalls and fed hay and water *ad-libitum*. Mean age of horses at the time of the study was 12.2 years (+/- SD 6.0, range 7.0 to 25.0 years). Daylight length was 13.9 hours (+/- 3.1, range 9.4 to 16.8 hours). All animal manipulations were approved by the University of Saskatchewan's Animal Research Ethics Board and adhered to the Canadian Council on Animal Care guidelines for humane animal use.

On the day of catheter placement (Day 0), horses were sedated using a combination of detomidine hydrochloride^a [3 mg intravenously (IV)] and butorphanol tartrate^b [3 mg IV] administered via the jugular vein. The horses remained free-standing (restrained with a head halter and lead rope but not placed in stocks) during the subsequent procedures, to reduce the stress associated with the procedure and any subsequent effect on endogenous

ACTH concentration. The jugular furrows were clipped of hair and aseptically prepared. Hair immediately rostral to the masseter muscle mass on the left side of the face was clipped and similarly prepared. The facial vein was palpated in this region and 12 mL of 2% mepivacaine^c was infiltrated into the dermal and subdermal layers of the proposed 6 cm incision site using a 20 gauge (G) needle. The technique of Irvine and Alexander (1987) was followed. Briefly, a vertical skin incision was made through the skin overlying the facial vein. The sub-cutaneous tissues were carefully dissected to expose the vein, artery and parotid salivary duct. The vein was isolated and elevated using a loop of 2/0 polydioxanone^d suture. A #11 scalpel blade was used to make a small puncture into the vessel and a 7 French (Fr) G 110 cm pulmonary artery balloon^e (Swan Ganz) catheter was introduced. The catheter was advanced 30 cm through the vein into the cavernous sinus and then the pre-placed suture was used to fix the catheter within the vessel, thereby occluding it. The vein was then allowed to retract into the incision which was sutured closed in 2 layers (sub-cutaneous layer and skin). The remaining length of the catheter was secured on the head using cyanoacrylate glue and the head was bandaged to protect the incision and catheter. The correct position of the catheter was determined using radiographic confirmation initially and subsequently using a characteristic behavioral response that included widening eyes and cessation of chewing activity and a slight backward movement away from the horse handler, while the catheter was flushed with heparinized saline. This response did not diminish over the entire study period. The catheter was flushed every 8 hours to maintain patency using 3 mL of heparinized saline.

The following morning (Day 1) horses were restrained in box stalls using a head halter and lead rope. Feed was placed at head-height to encourage the horse to remain still. A 3-way stopcock was placed onto the external end of the Swan-Ganz catheter, which was retracted to approximately 25 cm, and 12 mL of blood was obtained every 5 minutes for 1 hour. The same volume of blood was concurrently removed from the ipsilateral jugular vein by venipuncture at 0, 30, and 60 minutes. As a result 13 cavernous sinus samples and 3 jugular blood samples were collected from each horse. Blood was placed into plastic tubes containing EDTA, stored on ice during the collection period and then centrifuged at 4000 rpm for 15 minutes at 4 °C. Plasma was decanted into Eppendorf tubes and frozen at -80 °C, within 2 hours of collection.

On the day of general anesthesia (Day 2), a 14G 133 mm over-the-needle catheter^f was placed in the left jugular vein for administration of lactated Ringers solution (10 mL/kg/hour) and drugs. Horses were sedated with xylazine hydrochloride^g [1mg/kg IV] and anesthesia was induced with ketamine^h [2 mg/kg IV] mixed with propofolⁱ [0.4 mg/kg IV]. The trachea was intubated using a 26 mm internal diameter cuffed endotracheal tube and the horse hoisted onto a padded operating table and placed in dorsal recumbency. The endotracheal tube was attached to a large animal circle breathing system and the lungs ventilated^j with oxygen using 10 mL/kg as the tidal volume and the respiratory rate adjusted to achieve an end-tidal carbon dioxide (PE_TCO₂) of 45 +/- 5 mmHg (Wilson et al. 2006). Anesthesia was maintained with isoflurane^k in oxygen using a precision vaporizer. Butorphanol tartrate^b was administered [0.05 mg/kg IV] as soon as the horse was positioned on the operating table and infused at a rate of 0.01 mg/kg/hour

throughout the procedure using a computerized syringe pump. Dobutamine^l was used to maintain mean arterial blood pressure above 70 mmHg in all horses.

A side-stream gas analyzer^m measured end-tidal carbon dioxide (PE_{CO2}) and end-tidal isoflurane (PE_{Iso}) from a sampling port positioned in the 'Y' connector of the breathing circuit. The gas analyzer also displayed oxygen saturation of hemoglobin using a pulse oximeter probe placed on the tongue. A 20 SWG 48 mm over-the-needle catheterⁿ was percutaneously placed into a facial artery for measurement of systemic arterial blood pressures using a transducer^o positioned at the level of the shoulder (zero-point). The pressure waveform was transduced through saline-filled, non-compliant tubing and displayed using a physiological monitor^p. The physiological monitor calculated the heart rate from the arterial pressure waveform, and also displayed the electrocardiogram. Nasopharyngeal temperature was also measured in 4 horses using the same monitor.

One hour after inhalant anesthesia started, at approximately the same time of day as Day 1, the blood sampling protocol described above was repeated. At the end of the procedure, horses were euthanized using an overdose of sodium pentobarbital^q. The brain and pituitary gland were removed after euthanasia and no gross abnormalities (enlargement) of the pituitary gland were found. There were blood clots present within the cavernous sinus, with no apparent difference between the side containing the catheter and the non-catheterized side.

Plasma ACTH concentrations were measured using a commercial sandwich assay^r. The samples and controls (bi-level ACTH control module)^s, were thawed and maintained on

ice until analysis. Analyses were performed over 2 days. Intra- and inter-assay coefficients of variation were 1.7% to 2.3% (n = 5) and 2.3% to 2.9% (n = 8) for control sera with mean ACTH concentrations of 30.4 or 400.0 pg/mL, respectively. The manufacturer's stated analytical sensitivity was 9 pg/mL.

Data pertaining to the horse (age, sex, breed, date of the procedure and daylight length, standing or anesthetized and site and time of blood collection as well as plasma ACTH concentration) were recorded on a spreadsheet program^t and subsequently transferred to Windows based statistical programs.^{u,v}

Plasma ACTH concentrations were log-transformed to establish normality and generalized estimating equations assuming a normal distribution, controlling for repeated observations on individual horses were used to examine the effects of age, breed, sex, blood sample site (jugular vein or cavernous sinus), daylight length, time of blood sample and standing versus general anesthesia as variables on log-transformed plasma ACTH concentrations. All potential variables were initially screened using univariable analysis and variables for which the p-value was < 0.2 were submitted for consideration in building the final multivariate model (Dohoo et al. 2012). All final models were built using manual backwards elimination. Variables that were not significant were assessed as potential confounders. Where 2 or more variables were significant, biologically plausible 2-way interactions were assessed with significant interactions retained in the final model (p < 0.05). Model residuals were examined to detect outliers and influential observations.

Furthermore, ACTH concentration time series, i.e., the collection of all cavernous sinus blood samples for each horse at each time-point, before and during isoflurane anesthesia were analyzed by means of an expressly automated deconvolution algorithm. A convolution integral was employed to “deconvolve” or to separate out the processes which give rise to the overall temporal behavior of the hormone in the data. These components consist of the rate of hormone entry into the bloodstream and the rate of hormone removal from the bloodstream. Automated deconvolution is characterized as a multi-parametric deconvolution-based hormone pulse identification method and considers 4 order specific numbers: namely hormone concentration, an estimate of the precision of the hormone concentration, the time value, and the number of sample replicates. Automated deconvolution is superior to the discrete peak-detection methods in locating hormone secretion events as it provides crucial information about basal secretion, secretion-event pulse mass (pulse secretion), and elimination half-lives (Johnson et al. 2004)^w. Parameters generated via deconvolution analysis were statistically evaluated by means of the paired t-test, after normality was checked using with the Kolmogorov-Smirnov test.

5.4 RESULTS

Physiologic data obtained from the horses during general anesthesia are presented in Table 5.1. There was no effect of age or daylight length on overall plasma concentration of ACTH, controlling for site of collection ($p = 0.21$ and 0.78 , respectively).

Table 5.1 Summary of specific physiological data collected for 6 horses during general anesthesia. (Data presented are mean +/- SD)

Variable	Time from Induction of Anesthesia (minutes)									
	30	40	50	60*	70	80	90	100	110	120
Mean Arterial Blood Pressure (mmHg)	64 ± 14	72 ± 10	71 ± 6	72 ± 17	70 ± 13	71 ± 6	74 ± 8	67 ± 8	71 ± 9	69 ± 7
Heart Rate (Beats per minute)	37 ± 7	34 ± 5	33 ± 5	33 ± 2	34 ± 3	34 ± 4	36 ± 8	37 ± 8	37 ± 9	38 ± 12
End Tidal CO ₂ (mmHg)	48 ± 5	46 ± 3	46 ± 3	44 ± 3	44 ± 3	43 ± 2	43 ± 3	43 ± 2	44 ± 2	44 ± 2
Nasopharyngeal Temperature (°C)	36.3 ± 0.3	36.3 ± 0.4	36.2 ± 0.5	36.1 ± 0.5	36.0 ± 0.6	36.0 ± 0.5	35.8 ± 0.4	35.8 ± 0.5	35.7 ± 0.5	35.7 ± 0.5
Hemoglobin Oxygen Saturation (%)	96 ± 3	96 ± 3	97 ± 3	97 ± 2	96 ± 4	96 ± 4	96 ± 3	95 ± 3	96 ± 3	96 ± 3
End Tidal Isoflurane Concentration (%)	1.5 ± 0.2	1.5 ± 0.2	1.5 ± 0.2	1.5 ± 0.3	1.6 ± 0.3	1.6 ± 0.2	1.6 ± 0.2	1.6 ± 0.2	1.6 ± 0.2	1.6 ± 0.2

* Start of Blood Sampling

Plasma ACTH concentration was significantly higher in cavernous sinus blood (499 pg/mL +/- 190) than in peripheral blood (49 pg/mL +/- 28, $p < 0.001$, Table 5.2).

Discrete peak detection revealed reduced average ACTH concentration per time series (from 549 +/- 888 to 439 +/- 668 pg/mL; $p = 0.044$) and the area under the concentration curve (from 35.2 +/- 58.0 to 28.5 +/- 43.4 ng/mL/hour; $p = 0.046$) during isoflurane anesthesia. Discrete peak detection detected 1 concentration peak per time series, whereas automated deconvolution analysis detected 4 secretion peaks in total, namely in 3 standing horses (Table 5.3; ACTH half-life of 12.0, 9.2, and 2.4 minutes) and 1 out of 6 horses during isoflurane anesthesia (ACTH half-life of only 0.3 minutes).

5.5 DISCUSSION

The effect of anesthesia on the physiological stress response has been classically measured using peripheral plasma hormone concentrations, yet the effect on pulsatility has not been evaluated. Our results indicate that isoflurane anesthesia leads to a reduction in mean ACTH concentration in the cavernous sinus of the horse and a decrease in the area under the curve (AUC). These results may be a function of an anesthesia induced reduction in the half-life of ACTH, but further work is necessary to definitively determine this. The reduction in mean ACTH concentration under anesthesia is different from earlier studies. Some, using halothane or a similar anesthetic protocol to the one we used, showed either an increase in ACTH concentration (Taylor 1989, 1991; Luna and Taylor 1995), whereas others using isoflurane-anesthetized horses (Dzikiti et al. 2003), showed

Table 5.2 Mean plasma ACTH concentrations (pg/mL) at varying time points (minutes) illustrating differences between standing position (S) and general anesthesia (A), and between peripheral (P) and cavernous sinus (C) blood. NP* = Not Performed

Time (minutes)	Position Standing (S) General Anesthesia (A)	Cavernous Sinus (C) or Peripheral(P) blood	Mean concentration (pg/mL)	Standard Deviation
0	S	C	276.2	322.9
		P	17.5	9.7
	A	C	393.4	585.1
		P	90.6	189.8
5	S	C	136.2	172.6
		P	NP*	NP
	A	C	1247.3	2350.6
		P	NP	NP
10	S	C	308.6	298.5
		P	NP	NP
	A	C	257.1	384.4
		P	NP	NP
15	S	C	508.0	440.6
		P	NP	NP
	A	C	363.7	585.2
		P	NP	NP
20	S	C	599.2	733.4
		P	NP	NP
	A	C	549.2	1089.1
		P	NP	NP
25	S	C	1068.7	2164.5
		P	NP	NP
	A	C	500.23	1021.8
		P	NP	NP
30	S	C	1355.5	3001.4
		P	25.3	25.1
	A	C	572.5	1176.2
		P	69.7	69.8
35	S	C	538.2	1019.8
		P	NP	NP
	A	C	862.4	1934.7
		P	NP	NP

Table 5.2 (cont.) Mean plasma ACTH concentrations (pg/mL) at varying time points (minutes) illustrating differences between standing position (S) and general anesthesia (A), and between peripheral (P) and cavernous sinus (C) blood. NP* = Not Performed

Time (minutes)	Position Standing (S) General Anesthesia (A)	Cavernous Sinus (C) or Peripheral(P) blood	Mean concentration (pg/mL)	Standard Deviation
40	S	C	240.0	327.9
		P	NP	NP
	A	C	360.7	710.6
		P	NP	NP
45	S	C	341.1	420.9
		P	NP	NP
	A	C	307.4	411.1
		P	NP	NP
50	S	C	230.3	235.0
		P	NP	NP
	A	C	129.9	169.8
		P	NP	NP
55	S	C	268.6	483.2
		P	NP	NP
	A	C	82.4	70.3
		P	NP	NP
60	S	C	1446.0	2993.8
		P	35.6	40.9
	A	C	92.2	53.9
		P	53.9	38.3

Table 5.3 Outcome of deconvolution analysis, standing and under isoflurane anesthesia.

Mean +/- standard deviation. NS = Not significant

Parameter	Standing	Anesthesia	p-value
Mean ACTH Concentration (pg/mL)	549 +/- 888	439 +/- 668	0.044
Area Under the Curve (ng/mL/hour)	35.2 +/- 58.0	28.5 +/- 43.4	0.046
Number of secretion peaks	3	1	NS

no change in ACTH concentration. General anesthesia typically results in hypercapnia, hypoxemia, hypotension, and hypothermia. These physiologic alterations can cause an increase in sympathetic nervous system tone and stimulate a stress response.

In horses, a combination of more than 1 of these physiologic alterations may be necessary to increase stress hormone concentrations to a significant level (Taylor 1998). A previous study using pentobarbital in horses indicated preservation of arterial blood pressure may have decreased the physiological stress response compared to using halothane (Taylor 1990). In our study, arterial blood pressure was maintained using intravenous fluids and dobutamine and use of such treatment has been found to reduce cortisol release (Taylor 1998), which is a marker of physiological stress. However, simply maintaining arterial blood pressure with either dobutamine or methoxamine alone does not appear to completely remove the physiological stress response (Taylor 1998; Brodbelt 1998). The lungs of the horses in the current study were ventilated using a capnogram to guide ventilator settings. The capnogram can underestimate the true arterial carbon dioxide tension and, therefore, these horses may be considered mildly hypercapnic. Mild and severe hypercapnia alone, however, has not been found to increase cortisol concentration (Taylor 1990, 1998b; Khanna et al. 1995). In our horses, the pulse oximeter measurements were between 90% and 98%, but not less than 90%. The pulse oximeter has been found to underestimate the true hemoglobin oxygen saturation in horses, therefore, hypoxemia was unlikely (Koenig et al. 2003). However, arterial blood gas analysis was not performed to confirm the data obtained from the capnogram and pulse oximeter. The body temperature as measured in the nasopharyngeal area decreased over

time and hypothermia may initiate a physiological stress response, but mild hypothermia has been found to decrease the concentration of stress hormones (ACTH and cortisol) in humans (Oak et al. 2001).

Induction of anesthesia with xylazine and ketamine has not been found to increase serum cortisol in horses (Robertson 1987). Cortisol concentration did not increase until 60 and 80 minutes following xylazine administration in halothane and isoflurane anesthetized ponies, respectively (Taylor 1991). Alpha-2 adrenergic agonists are known to suppress the stress response, as determined by measuring plasma ACTH concentrations, by decreasing sympathetic tone (Taylor 1991; Alexander and Irvine 2000) and, therefore, the decision to begin collecting blood samples 60 minutes after induction was made to ameliorate the significant hypophyseal suppression occurring with xylazine given for premedication. However, the effect of xylazine alone on cortisol or ACTH concentration in the horses has not been well studied. Detomidine has been found to decrease or not change cortisol concentration in horses, and medetomidine or xylazine did not change cortisol concentration in dogs (Raekallio et al. 1992; Carroll et al. 1997; Ambrisko and Hikasa 2002). Butorphanol was used in this study as part of a concurrent study examining histamine release from use of opioids. Butorphanol infusions, however, have not been found to influence serum cortisol concentrations in horses under anesthesia (Dias et al. 2014). Propofol was used as a co-induction agent with ketamine and was unlikely to influence the results 60 minutes following the low dose used, although this has not been confirmed in horses (Ruane-O'Hara et al. 2011).

Cavernous sinus blood had significantly higher concentrations of plasma ACTH compared to jugular vein blood which can be explained by a dilutional effect of venous blood draining from other areas of the head and neck. The gradient in ACTH concentration between cavernous sinus and jugular plasma can be over 33 to 50-fold in the equine species (Luna and Taylor 1998), compared to the 10 to 20-fold (depending on the time-point) in the current study. When our results were compared to more commonly used discrete peak-detection methods, not only was the amount of ACTH secreted over the sampling period significantly reduced during anesthesia, but the number of concentration peaks were also minimal prior to and during anesthesia. No doubt the latter was due to differences in assay characteristics, specifically a rather high hormone detection limit of 9 pg/mL and a single replicate (measurement) used in this case. Furthermore, only a single secretion peak was noted under anesthesia, compared to only 3 secretion peaks detected in the unsedated standing horse. These differences are also likely due to the assay characteristics used by the automated deconvolution methodology.

The use of interventional radiological techniques for the intravascular treatment of a variety of neoplasms, developmental and acquired abnormalities is increasing in humans and small animals. In order to be confident of a treatment effect, other possible confounding factors such as pathophysiological effects of anesthesia and anesthetic drugs must be considered. The current study indicates that if manipulation of the pituitary gland *in-situ* is successful for the treatment of PPID, simple measurement of plasma ACTH concentration, especially if minimal, in cavernous sinus blood may not be a reliable indicator of interventional success which would have to be interpreted in light of effects

of general anesthesia. Further work is necessary to determine appropriate methods of assessing immediate effects of interventional therapies applied to the pituitary gland.

Footnotes:

^a Dormosedan, Pfizer Animal Health, Pfizer Canada Inc., Kirkland, QC, Canada

^b Torbugesic, Ayerst Laboratories, Pierrefonds, QC, Canada

^c Carbocaine, Pfizer Animal Health, Pfizer Canada Inc., Kirkland, QC, Canada

^d PDS II, Ethicon US LLC, Cincinnati, OH, USA

^e Swan-Ganz, Edwards Lifesciences LLC, Irvine, CA, USA

^f BD Angiocath, Becton Dickinson, Infusion Therapy Systems Inc., Sandy, UT, USA

^g Rompun, Bayer Healthcare, city, ON, Canada)

^h Vetalar; Bioniche Animal Health, Belleville ON, Canada

ⁱ Propoflo; Abbott Laboratories, Saint-Laurent, QC, Canada

^j Dräger AV, Anesthesia Ventilator, North American Dräger, Telford, PA, USA

^k Isoflo, Abbott Laboratories, Saint-Laurent, QC, Canada)

^l Dobutamine injection USP, Sandoz Canada Inc. Boucherville, QC, Canada

^m POET IQ Anesthesia Gas Monitor, Criticare Systems Inc., WI, USA

ⁿ BD Insyte, Becton Dickinson, Infusion Therapy Systems Inc., Sandy, UT, USA

^o Truwave Disposable Pressure Transducer, Edwards Lifesciences LLC, Irvine, CA, USA

^p PB240 Operating Room Monitor, Puritan Bennet Corporation, city, MA, USA

^q Euthanyl Forte, Bimeda-MTC Animal Health Inc., Cambridge, ON, Canada.

^r Siemens ACTH kit and Immulite 1000 Chemiluminescent System, Siemens Canada, Oakville, ON, Canada

^s bi-level ACTH control module, Siemens Canada Oakville, ON, Canada

^t Microsoft Excel, Microsoft Canada Inc, Mississauga, ON, Canada

^u SPSS, IBM Canada Ltd, Markham, ON, Canada

^v PULSE XP, Pulse Analysis Software, University of Virginia, Charlottesville, VA, USA.

^w https://www.researchgate.net/publication/262566415_AutoDecon_and_Pulse_XP_Software.

5.6 REFERENCES

Alexander SL and Irvine CHG. The effect of the alpha-2-adrenergic agonist, Clonidine, on secretion patterns and rates of adrenocorticotrophic hormone and its secretagogues in the horse. *J Neuroendocrinol* 2000; 12: 874-880

Alexander SL, Irvine CHG, Donald RA. Short-term secretion patterns of corticotropin-releasing hormone, arginine vasopressin and ACTH as shown by intensive sampling of pituitary venous blood from horses. *J Neuroendocrinol* 1994; 60: 225-236.

Alexander SL, Irvine CHG, Donald RA. Dynamics of the regulation of the hypothalamo-pituitary-adrenal (HPA) axis determined using a nonsurgical method of collecting pituitary venous blood from horses. *Front Neuroendocrinol* 1996; 17: 1-50.

Ambrisko TD and Hikasa Y. Neurohormonal and metabolic effects of medetomidine compared with xylazine in beagle dogs. *Can J Vet Res* 2002; 66: 42-49.

Biller BMK, Grossman AB, Stewart PM et al. Treatment of adrenocorticotropin-dependent Cushing's syndrome: A consensus statement. *J Clin Endocrinol Metab* 2008; 93: 2454-2462.

Bons J, Cornips E, Zwam W van, et al. ACTH measurements during surgery for Cushing's disease: a feasibility study. NVKC Voorjaarscongres. Veldhoven, the Netherlands. 9-11 April 2014

Brodbelt DC, Harris J, Taylor PM. Pituitary-adrenocortical effects of methoxamine infusion on halothane anaesthetised ponies. *Res Vet Sci* 1998; 65: 119-123.

Carroll GL, Matthews NS, Hartsfield SM et al. The effects of detomidine and its antagonism with tolazoline on stress related hormones, metabolites, physiologic responses and behavior in awake ponies. *Vet Surg* 1997; 26: 69-77.

Couëtil L, Paradis MR, Knoll J. Plasma adrenocorticotropin concentration in healthy horses and horses with clinical signs of hyperadrenocorticism. *J Vet Int Med* 1996; 10: 1-6.

Dias BP, De Araujo MA, Deschk M et al. Effects of an intravenous infusion of butorphanol in isoflurane-anesthetized horses on cardiorespiratory parameters, recovery quality, gastrointestinal motility and serum cortisol concentrations *Acta Cirurgica Brasileira* 2014; 29: 801-806.

Dohoo I, Martin W, Stryhn H. (2012) Model-building strategies. In: *Veterinary Epidemiologic Research*, 2nd Edn., VER Inc. Charlottetown, Prince Edward Island, Canada pp 365-394.

Dzikiti TB, Hellebrekers LJ, van Dijk P. Effects of Intravenous Lidocaine on Isoflurane Concentration, Physiological Parameters, Metabolic Parameters and Stress-related Hormones in Horses Undergoing Surgery. *J Vet Med A* 2003; 50: 190-195.

Irvine CH, Hunn R. Long term collection of pituitary venous blood in the unrestrained horse. *NZ Med J* 1984; 97: 735.

Irvine CHG, Alexander SL. A novel technique for measuring hypothalamic and pituitary hormone secretion rates from collection of pituitary venous effluent in the normal horse. *J Endocrinol* 1987; 113: 183-192.

Johnson ML, Virostko A, Veldhuis JD et al. Deconvolution analysis as a hormone pulse-detection algorithm. *Methods in Enzymology* 2004; 384: 40-54.

Khanna, AK, McDonnell WN, Dyson DH et al. Cardiopulmonary effects of hypercapnia during controlled positive pressure ventilation in the horse. *Can J Vet Res* 1995; 59: 213-221.

Koenig J, McDonnell WN, Valverde A. Accuracy of pulse oximetry and capnography in healthy and compromised horses during spontaneous and controlled ventilation. *Can J Vet Res* 2003; 67: 169-174.

Lee Z-Y, Zylstra R, Haritou SJ. The use of adrenocorticotrophic hormone as a potential biomarker of pituitary pars intermedia dysfunction in horses. *Vet J* 2010; 185: 58-61.

Luna SP and Taylor PM. Pituitary-adrenal activity and opioid release in ponies during thiopentone/halothane anaesthesia. *Res Vet Sci* 1995; 58: 35-41.

Luna SP, Taylor PM. Cortisol, peptides and catecholamines in cerebrospinal fluid, pituitary effluent and peripheral blood of ponies. *Equine Vet J* 1998; 30: 166-169.

McConaghy FF, Hales JR, Rose RJ et al. Selective brain cooling in the horse during exercise and environmental heat stress. *J Appl. Physiol* 1995; 79: 1849-1854.

McFarlane D. Equine pituitary pars intermedia dysfunction. *Vet Clin Equine* 2011; 27: 93-113.

McGowan TW, Pinchbeck GP, McGowan CM. Evaluation of basal plasma α -melanocyte-stimulating hormone and adrenocorticotrophic hormone concentrations for the diagnosis of pituitary pars intermedia dysfunction from a population of aged horses. *Equine Vet J* 2013; 45: 66-73.

Millington WR, Dybdal NO, Dawson R et al. Equine Cushing's disease: differential regulation of β -endorphin processing in tumors of the intermediate pituitary. *J Endocrinol.* 1988; 123: 1598-1604.

Oak ZC, Young KC, Doo IL et al. Intraoperative mild hypothermia does not increase plasma concentrations of stress hormones during neurosurgery. *Can J Anaes* 2001; 48: 815-818.

Raekallio M, Leino A, Vainio O et al. Sympatho-adrenal activity and the clinical sedative effect of detomidine in horses. *Equine Pharm* 1992; Suppl 11: 66-68.

Robertson SA. Some metabolic and hormonal changes associated with general anesthesia and surgery in the horse. *Equine Vet J* 1987; 19: 288-294.

Ruane-O'Hara T, Hall WJ, Markos F. The effect of alphaxalone-alphadolone, propofol, and pentobarbitone anaesthesia on the β -endorphin and ACTH response to haemorrhage in the pig. *Can. J. Physiol. Pharmacol* 2011; 89: 521-526.

Sakes A, Arkenbout EA, Jelínek F, et al. Design of an endovascular morcellator for the surgical treatment of equine Cushing's disease. *Vet Q* 2015; 35: 165-169.

Taylor PM. Equine stress responses to anaesthesia. *Br. J. Anaesth* 1989; 63: 702-709.

Taylor PM. The stress response to anaesthesia in ponies: barbiturate anaesthesia. *Equine Vet J* 1990; 22: 307-312

Taylor PM. Stress responses in ponies during halothane or isoflurane anaesthesia after induction with thiopentone or xylazine/ketamine. *J. vet. Anaesth* 1991; 18: 8-14.

Taylor PM. Adrenocortical and metabolic responses to dobutamine infusion during halothane anesthesia in ponies. *J vet Pharmacol Therap* 1998; 21: 282-287.

Taylor PM. Effects of hypercapnia on endocrine and metabolic responses to anaesthesia in ponies. *Res Vet Sci* 1998b; 65: 41-46.

van der Kolk JH, Wensing T, Kalsbeek HC et al. Laboratory diagnosis of equine pituitary pars intermedia adenoma. *Domest Anim Endocrinol* 1995; 12: 35-39.

Wilson DV, Schott HC, Robinson NE et al. Response to nasopharyngeal oxygen administration in horses with lung disease. *Equine Vet J* 2006; 38: 219-223.

CHAPTER 6

DEVELOPMENT OF A NOVEL SURGICAL APPROACH TO THE TREATMENT OF PITUITARY PARS INTERMEDIA DYSFUNCTION IN THE HORSE

CHAPTER 6

TRANSITION PAGE

Development of a novel surgical approach to the treatment of pituitary pars intermedia dysfunction in the horse.

This chapter presents the progression through various surgical approaches to the treatment of PPID in the horse and settles on a minimally invasive trans-venous fluoroscopic guided injection of the pituitary gland. The benefits and drawbacks of each method is explained and an in-depth assessment of the benefits of the minimally invasive method is given.

This work is important because it forms the basis for the next step in this line of investigation. The surgical manipulation of the gland in PPID horses will bring about a single intervention leading to palliation, or permanent cure of the condition in the affected horse.

Copyright statement: This Chapter has been submitted for publication. The copyright of this Chapter will belong to the journal in which it is published.

Full citation: Carmalt JL and Scansen BA. Development of a novel minimally invasive surgical approach to the treatment of PPID in the horse. *Veterinary Surgery* 2017. Submitted.

Author contributions: Carmalt conceptualized and tested the myeloscopic approach (a modification of a previously published technique). Carmalt (together with graduate and

summer students) conceptualized, designed and tested the trans-sphenopalatine sinus and the trans-basisphenoidal osteotomy approaches. Carmalt modified a previously published minimally invasive blood collection technique to approach the pituitary gland for treatment purposes and Scansen provided expertise in fluoroscopic guidance and interventional radiological techniques. Carmalt wrote the manuscript with Scansen providing editorial assistance.

6.1 ABSTRACT

Objective: To develop a safe, repeatable surgical modality for the treatment of pituitary pars intermedia dysfunction (PPID) in the horse.

Materials and Methods: Four surgical approaches to the pituitary gland were investigated: a myeloscopic technique via the foramen magnum, a trans-sphenopalatine sinus technique via maxillary sinusotomies, a ventral trans-basisphenoidal osteotomy and a minimally invasive intravenous approach via the ventral cavernous sinus.

Results: Significant bleeding and a failure to obtain the correct angle of approach prevented the myeloscopic and trans-sphenopalatine sinus techniques from being successful. The ventral basisphenoidal osteotomy was repeatable and has potential if an intra-operative imaging guidance system could be employed. The minimally invasive approach was repeatable, atraumatic and relatively inexpensive.

Conclusions: Current treatment of PPID typically requires daily oral medication, which is expensive and difficult from a management perspective. A minimally invasive surgical palliation of this chronic condition is appealing because it is envisioned to be a single treatment which, while not curative, will return the horse to a symptom-free state and dramatically improve the welfare of the horse. More work is necessary to determine what that treatment might be, but for the current time, access to the pituitary gland has been obtained, which is a promising step.

6.2 INTRODUCTION

Pituitary pars intermedia dysfunction (PPID) or equine Cushing's disease is a common endocrine disease of the older horse. Dopamine released by hypothalamic neurons inhibits proopiomelanocortin (POMC) production in the pars intermedia of normal horses. A loss of this control leads to hypertrophy and hyperplasia of pars intermedia melanotrophs with concomitant increases in the production of POMC (Millington et al. 1998; McFarlane 2011). This 241 amino acid propeptide is subsequently cleaved into smaller peptides by prohormone convertase enzymes. These include adrenocorticotrophic hormone (ACTH₁₋₃₉; 138-176 amino acid segment of POMC) as well as other POMC-derived peptides.

PPID horses with hypertrophy and hyperplasia of the pars intermedia have a grossly enlarged pituitary gland (van der Kolk et al. 2004; McFarlane et al. 2011; Leitenbacher and Herbach 2016). The relative positioning of this region of the gland, which is sandwiched between the pars distalis and the pars nervosa, makes selective pars intermedia ablation complicated. Complete ablation of the pituitary gland would result in a multitude of other hormonal imbalances which would require daily medication, which is no better than the current standard of care treatment regime involving daily oral pergolide, a dopamine receptor agonist.

The preferred method of treating ACTH-dependent hyperadrenocorticism in people and dogs is the surgical ablation of hypophyseal adenomata (Biller et al. 2008; Meij et al.

1998; Mamelak et al. 2014). Brain surgery is rarely performed in the horse. There are single case reports of the drainage of brain abscesses after localization using computed tomography (CT) (Allen et al. 1987; Cornelisse et al. 2001; Janicek et al. 2006), and a CT-guided biopsy of an intra-cerebral mass, which was subsequently diagnosed as a cholesterinic granuloma (Vanschandevijl et al. 2008). Kramer et al. (2007) reported on 3 approaches to the equine cranium (rostromental, suboccipital and the transfrontal) in cadaver heads, which gave limited access to the rostral, dorsal and caudal aspects of the cerebral cortex and cerebellum. No described approach gave access to the hypophysis. There is a single case report of an open craniotomy and severing of the hypothalamic-pituitary axis using a laser (Locatelli 1984), which unfortunately does not describe the technique or outcome sufficiently well to allow repetition.

Other possible options for hypophyseal access include myeloscopy which has been described for visualization of the floor of the vertebral canal in cases of cervical vertebral malformation (Prange et al. 2011a, 2011b, 2012); a trans-sphenopalatine sinus approach modelled on the human techniques; a ventral trans-basisphenoidal osteotomy; and a transcatheter approach utilizing access to the cavernous sinus of the horse originally published as a technique for pituitary effluent blood sampling (Irvine and Hunn 1984; Irvine and Alexander 1987; Alexander et al. 1994, 1996; Bons et al. 2014; Sakes et al. 2015).

The hypothesis of this study was that a surgical approach to the equine pituitary gland is feasible allowing for the further development of methods to ablate the pars intermedia.

The objective of the study was to develop a novel surgical technique for access to the pituitary gland in the horse.

6.3 MATERIALS AND METHODS

All of the procedures documented below were performed on cadaver heads, or in complete horse carcasses (unless otherwise expressly stated) during the development phase. Two of the procedures were subsequently performed in the live horse under a terminal general anesthesia protocol. All animals and cadaveric parts were used under approval of the Institutional Animal Use and Care Committee of the institution in which the work was performed.

6.3.1 MYELOSOPIC APPROACH

Two entire cadavers were used for the development of this technique. A variation of the previously published cervical myelotomy technique was used but altered such that the endoscope was directed cranially, rather than caudally (Prange et al. 2011a,b, 2012).

Briefly, the cadavers were placed in right lateral recumbency with the head flexed by tying the head collar to the proximal forelimbs. A dorsal midline incision was made centered on the cranial edge of the atlas and the underlying musculature separated. The epidural space was entered and the slim endoscope^a advanced abaxially and cranially under the spinal cord to enter the cranium through the foramen magnum. In each horse, significant hemorrhage was encountered during the approach. Despite repeated flushing

of the endoscope portal using lactated Ringers' solution, visualization was impaired to the point that the procedure was terminated.

6.3.2 TRANS-SPHENOPALATINE SINUS APPROACH

Five cadaveric heads, collected immediately postmortem and frozen until use at -20 °C were used. Heads were thawed in warm water for 24 hours and subsequently drained of water before use. Heads were positioned with the mandibles on a non-slip table to mimic sternal recumbency under general anesthesia.

A 2 cm incision was made parallel to the long axis of the head, 4 cm rostral to the palpable limit of the medial canthus of the eye and 4 cm lateral to the midline of the head on the left side. The skin was separated using hemostats and the underlying bone exposed. The rostral region of the dorsal conchal sinus was entered using a 9 mm Galt trephine. A 6 mm outer diameter flexible endoscope with a working biopsy channel^a was used to explore the caudal maxillary sinus system and the entrance to the sphenopalatine sinus. Under visual endoscopic guidance, a caudally facing obliquely angled hole was then made using the same technique immediately under the bony portion of the nasolacrimal duct half the distance between the medial canthus of the eye and the palpable border of the infraorbital foramen. A 2 mm orthopedic drill bit was introduced into the second hole and visually directed into the opening of the sphenopalatine sinus. Unfortunately this placed the tip of the bit too rostral and the working osteotomy was subsequently moved further rostral, entering the rostral maxillary sinus. The ventral

conchal bulla then had to be removed using biopsy forceps through the flexible endoscope so that the drill tip could pass through the caudal maxillary sinus and enter the ostium of the sphenopalatine sinus. Despite this modification, the caudal extent of the sphenopalatine sinus could not be accessed on the ipsilateral side and as such the technique was abandoned.

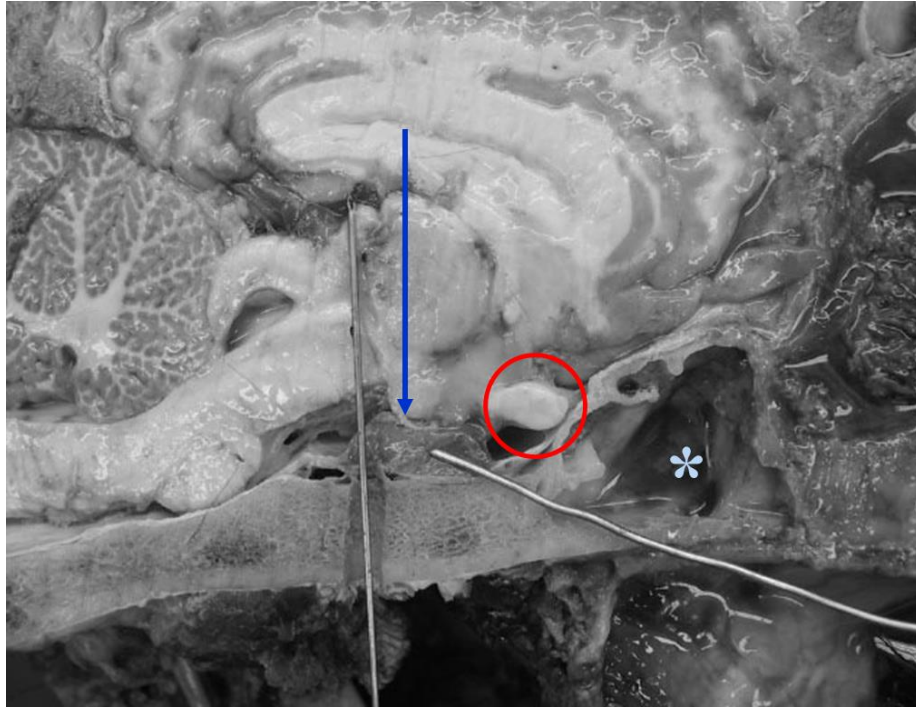
6.3.3 VENTRAL TRANS-BASISPHEOIDAL OSTEOTOMY APPROACH

Five cadaveric heads, collected immediately postmortem and frozen until use at -20 °C were used. Heads were thawed in warm water for 24 hours and subsequently drained of water before use. Heads were positioned to mimic dorsal recumbency under general anesthesia and the nose was tipped up to ensure that the base of the skull was parallel to the surgery table.

A flexible endoscope^a was advanced via the right external nares and the ventral nasal meatus into the nasopharynx. A 25W diode laser fiber^b was passed via the biopsy portal and the tissue of the dorsal pharyngeal recess was ablated using contact mode, as previously published for the treatment of guttural pouch tympany in foal (Edwards and Greet 2007). This allowed simultaneous entry into both guttural pouches and resection of the membrane separating the left and right pouches. A standard laryngotomy approach was made (Fulton et al. 2012) by creating a 10 cm incision on the ventral midline starting immediately caudal to the palpable margin of the thyroid cartilage and proceeding caudally to the cricoid cartilage. The sternothyrohyoideus muscles were separated through

their aponeuroses and retracted using Weitlaner retractors. The loose adventitial tissue overlying the cricothyroid membrane was separated, taking care to ligate the small vessel usually present in this location. The cricothyroid membrane and the mucosa of the airway on the dorsal aspect were sharply transected with a #10 scalpel blade. A long, 12 mm wide standard laparoscopic trochar and cannula^c was then advanced into the laryngotomy. The trochar was slightly withdrawn to allow the smooth edge of the cannula to sit between the corniculate processes of the arytenoid cartilages. By angling the cannula slightly rostrally while engaging the position and then moving it to a vertical position the entire larynx was displaced caudally. The sharp trochar was re-introduced and using verbal guidance from an assistant sighting midline of the horse and another checking the verticality of the cannula, in addition to using visual guidance from the flexible endoscope placed within the guttural pouch, the cannula was thrust through the roof of the nasopharynx. It was advanced until the tip of the trochar engaged the basisphenoid bone immediately rostral to the insertion of the paired longus capitis and longus capitis ventralis muscles within the guttural pouch. The trochar was removed and an auger drill bit, which had a guiding thread on the distal extent, was fed into the cannula to protect the surrounding soft tissues. A slot osteotomy was drilled through the basisphenoid bone under visual and digital radiographic guidance and then laparoscopic forceps were used to remove the final pieces of bone and confirm entry into the cranium. In this position, the pituitary gland was visible immediately under the bone, fixed to the floor of the sella turcica, and the ventral cavernous sinuses were abaxial to the drill hole (Figure 6.1).

Figure 6.1 A photograph of the brain and caudal nasal passages of an equine cadaver head. Rostral is to the right and caudal to the left.



Legend: The blue arrow denotes the hypothalamus, the red circle denotes the optic chiasm and the blue star illustrates the position of the sphenopalatine sinus. The oblique metal rod indicates the position of the pituitary gland while the vertical rod indicates a trans-basisphenoid approach to the gland which has been positioned too far caudally.

Following cadaveric success, the procedure was performed in a single, live horse under a terminal anesthetic protocol.

6.3.4 INTRAVENOUS (MINIMALLY INVASIVE) APPROACH

Three cadaveric heads, collected immediately postmortem and frozen until use at -20 °C were used. Heads were thawed in warm water for 24 hours and subsequently drained of water before use. Heads were positioned to mimic right lateral recumbency under general anesthesia and the nose was tipped up to ensure that midline of the skull was parallel to the fluoroscopy system^d.

The technique of Irvine and Alexander (1987) was followed. Briefly, the hair immediately rostral to the right masseter muscle mass on the lateral aspect of the face was clipped and aseptically prepared to remove surface debris and hair particles. A vertical skin incision was made through the skin overlying the deep facial vein. The subcutaneous tissues were carefully dissected to expose the deep facial vein, the facial artery and parotid salivary duct. The vein was isolated and elevated using a loop of 2/0 polydioxanone suture. A #11 scalpel blade was used to make a small puncture into the vein and a 7 French (Fr) gauge (G) 110 cm pulmonary artery balloon catheter (Swan-Ganz)^e was introduced (Figure 6.2 and 6.3A, B). The catheter was advanced 25 cm and correct placement within the ventral cavernous sinus (Figure 6.4) was confirmed by injecting 5 mL of 240 mgI/mL Iohexol contrast solution^f and visualizing the contrast column fluoroscopically in the lateral and ventrodorsal imaging planes.

Figure 6.2 A cadaver dissection showing the position of the vein, artery and parotid salivary duct (yellow arrow) in a mature horse. Rostral is to the left.

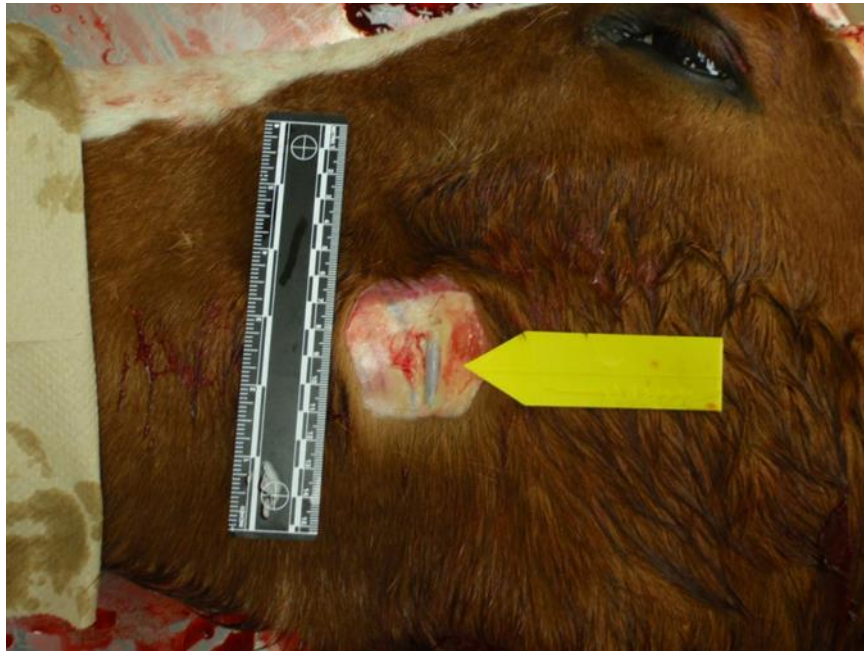

Figure 6.3A Placement of the Swan-Ganz catheter in the left deep facial vein. Rostral is to the left.

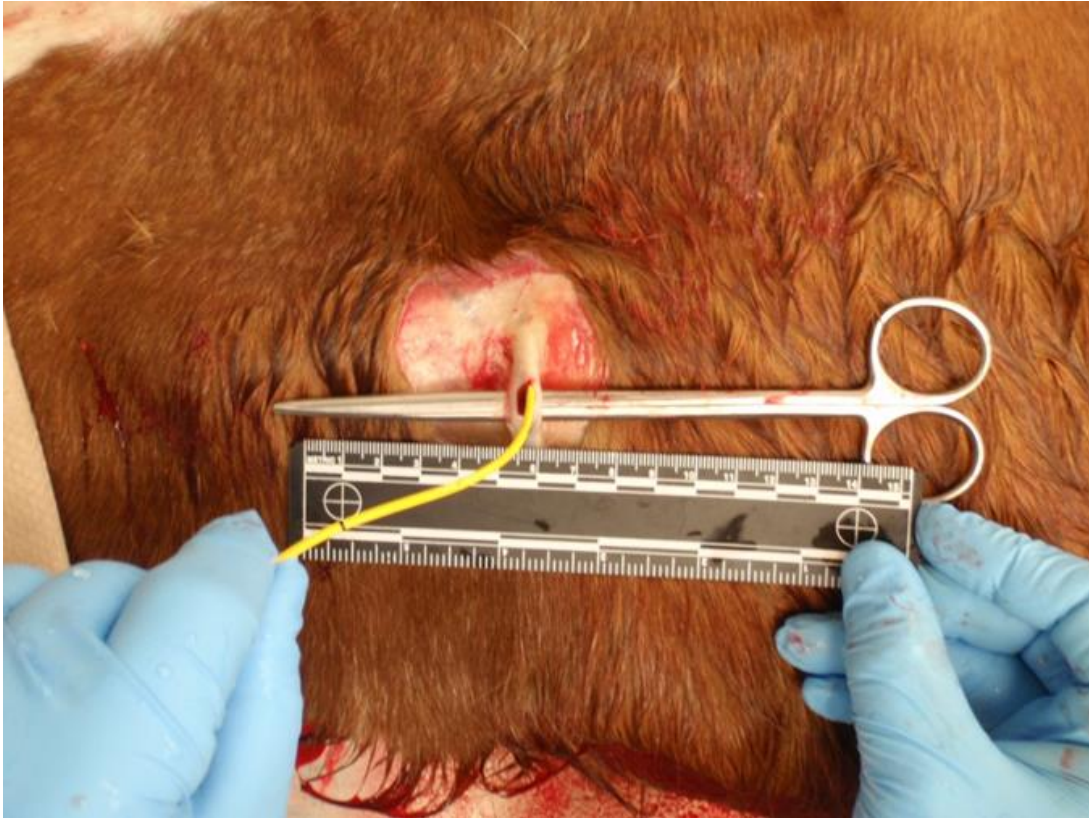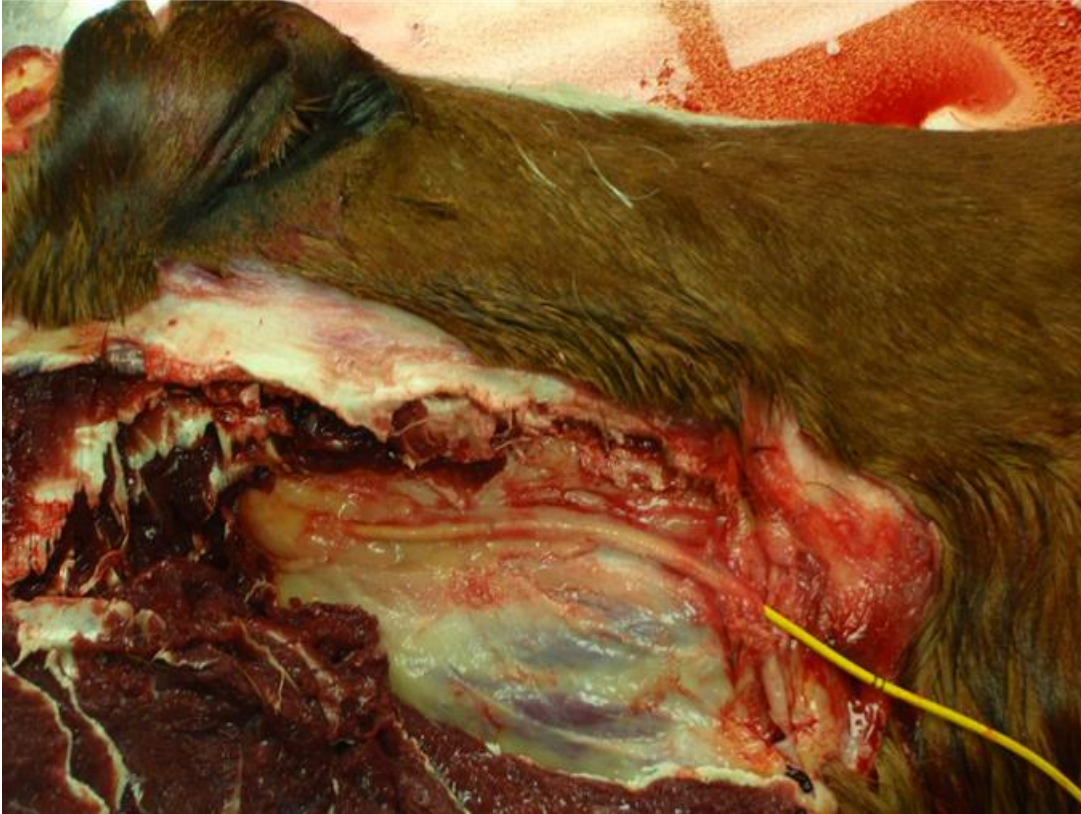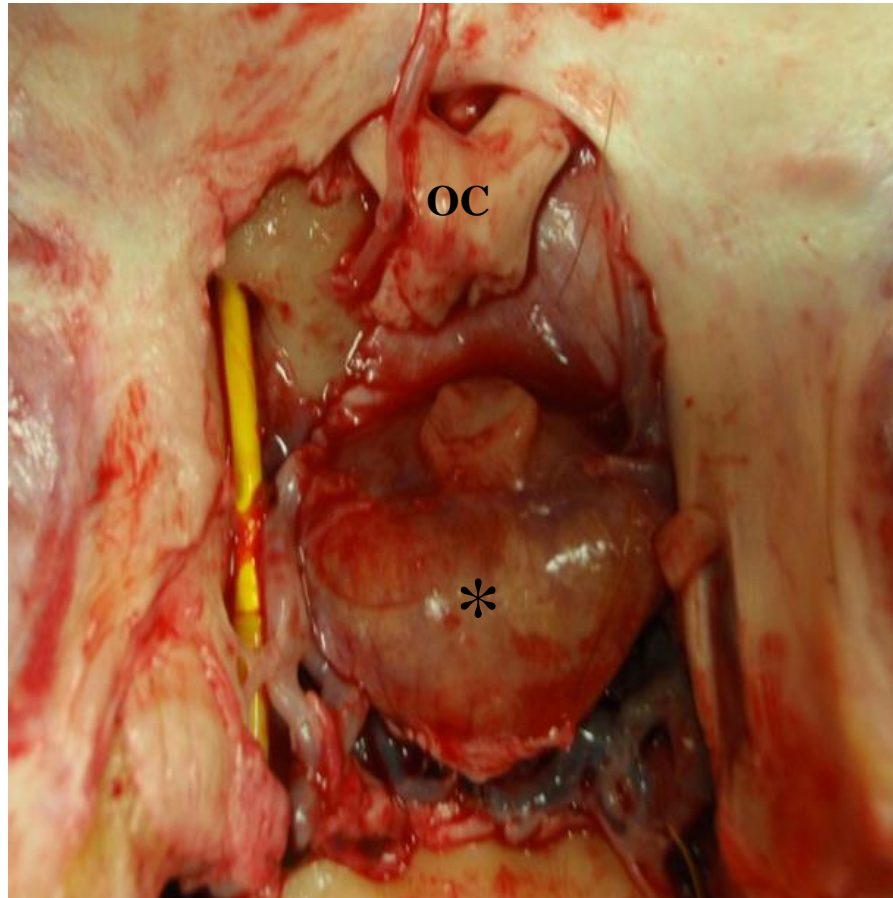


Figure 6.3B A cadaver dissection showing the catheter advanced via the right deep facial vein into the orbital fissure. Rostral is to the right.*



* See Chapter 1 for a description of the venous drainage of the ventral cavernous sinus.

Figure 6.4 A cadaver dissection, showing the placement of the 7FG Swan-Ganz catheter in the ventral cavernous sinus of the brain having entered via the orbital fissure.*



Legend: Note the position of the catheter lateral to the retained pituitary gland (*). The optic chiasm is noted (OC).

* See Chapter 1 for a description of the venous drainage of the ventral cavernous sinus.

Correct entry into the cavernous sinus resulted in visible contrast flow around a large, central filling defect, which was the pituitary gland (Figure 6.5A and B).

A 0.038” diameter, 145 cm length fixed core straight guide wire was advanced within the Swan-Ganz catheter to the cavernous sinus under fluoroscopic guidance and the Swan-Ganz catheter was then withdrawn. A 45 cm 8Fr G angled introducer sheath was advanced over the guide wire, and the tip of the sheath positioned within the cavernous sinus using intermittent administration of iohexol contrast solution and fluoroscopy to confirm location. When in the correct position, the wire guide was removed and replaced with a 56 cm 22Fr G trans-septal needle¹. The needle was passed through the sheath and directed into the pituitary gland under fluoroscopic guidance. The gland was then injected with a combination of radiopaque contrast material and new methylene blue dye. Confirmation of gland injection was accepted when “tumor blush” was seen fluoroscopically (Figure 6.6). Instrumentation was removed and the cranium was opened. The brain was removed leaving the pituitary gland in-situ and new methylene blue dye could be visually appreciated within the glandular tissue.

The same procedure was then performed in a live, clinically normal horse and a single aged mare with hirsutism and laminitis (consistent with PPID) under terminal anesthetic procedures.

Figure 6.5A A dorso-ventral fluoroscopic image of the cranium showing the catheter tip (arrows) adjacent to the pituitary gland (not visible). The caudal aspect of the pituitary gland is indicated by the tip of the scissors placed within the foramen magnum of the cadaveric head and advanced until the gland was touched.

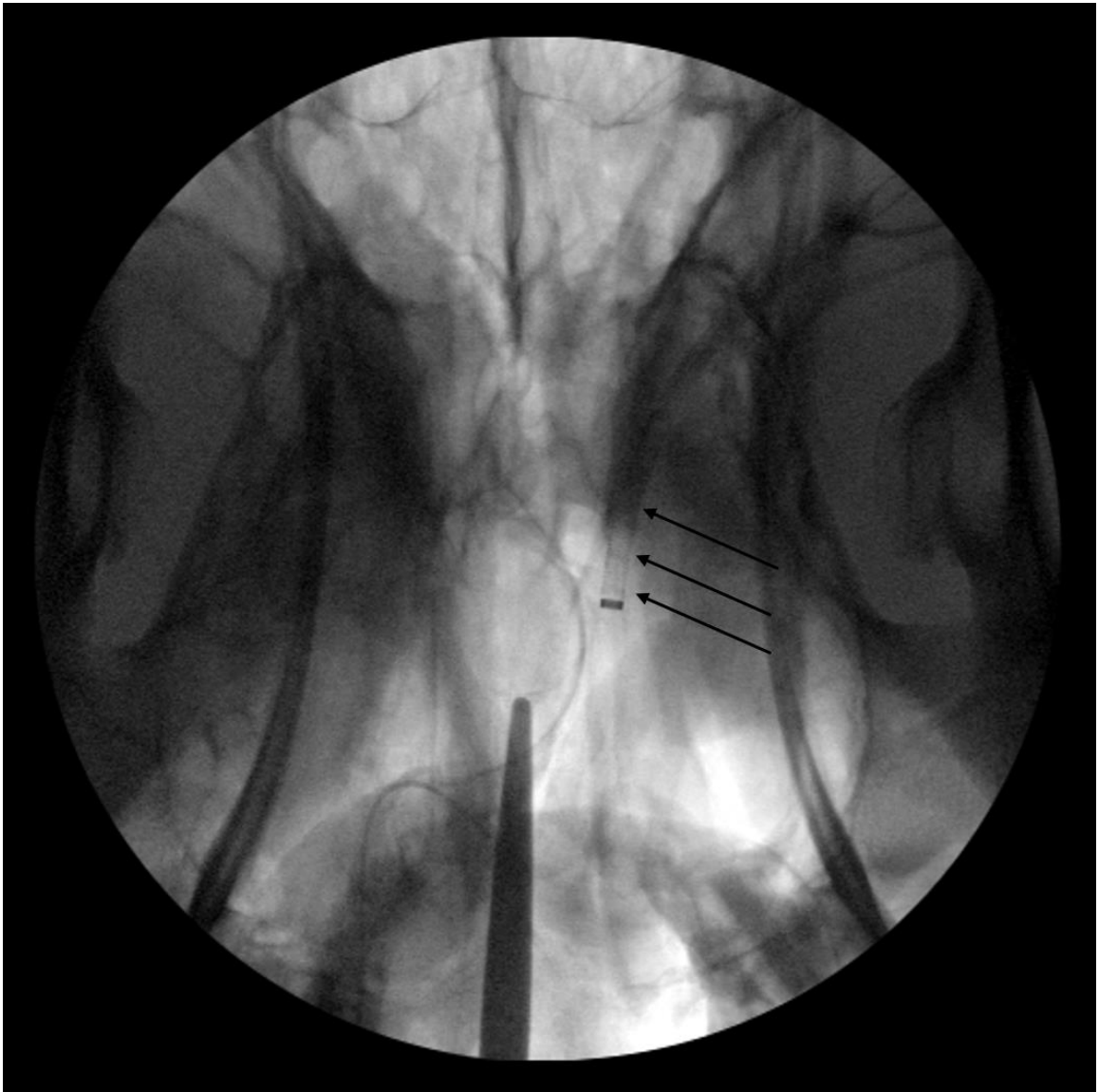


Figure 6.5B A dorso-ventral fluoroscopic image of the cranium showing contrast flow in the ventral cavernous sinus around a central filling defect which represents the pituitary gland. Note the presence of the catheter (black arrow), the flow of contrast material into the emissary veins (white arrows) and the central defect representing the pituitary gland (star)

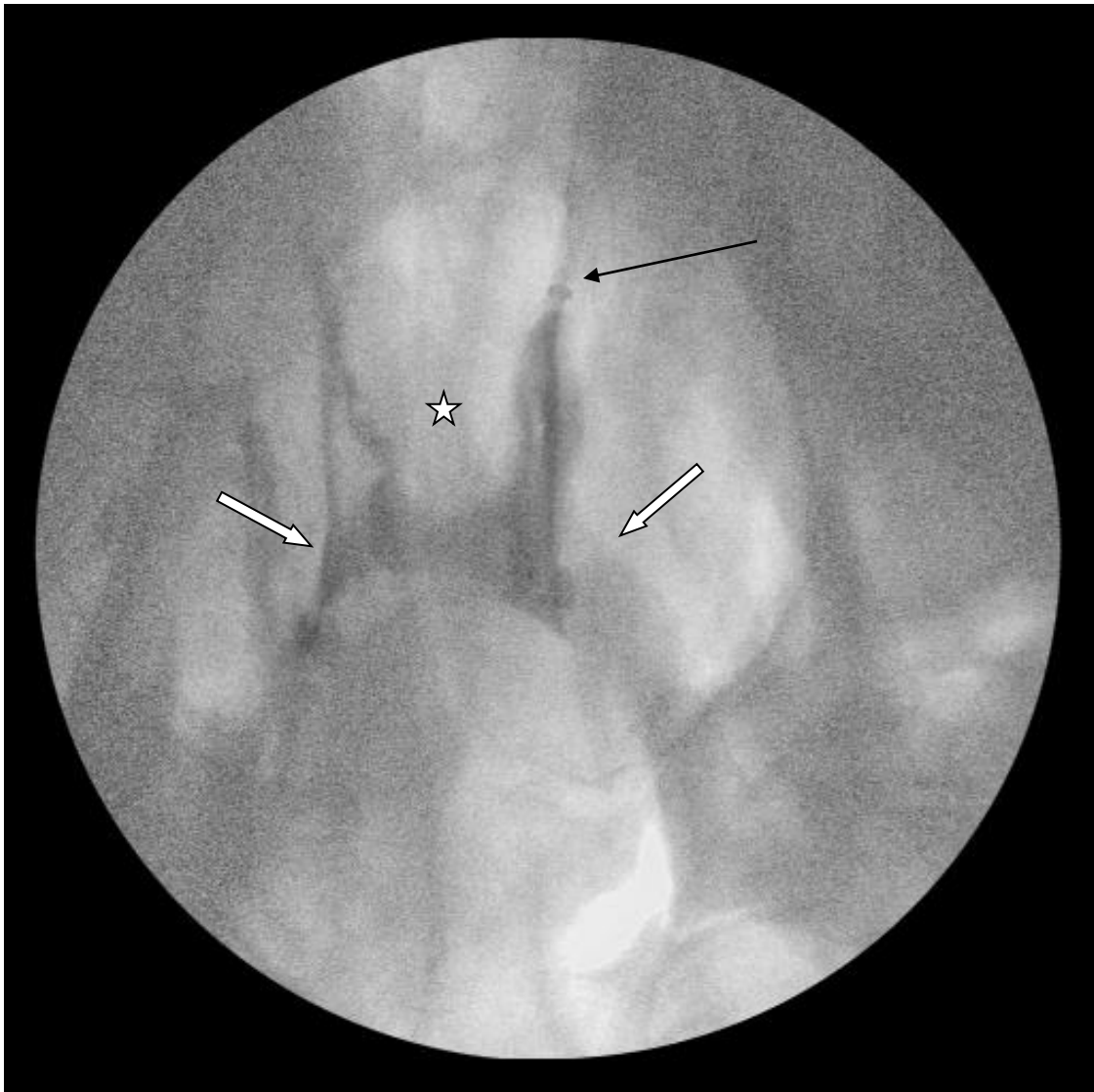
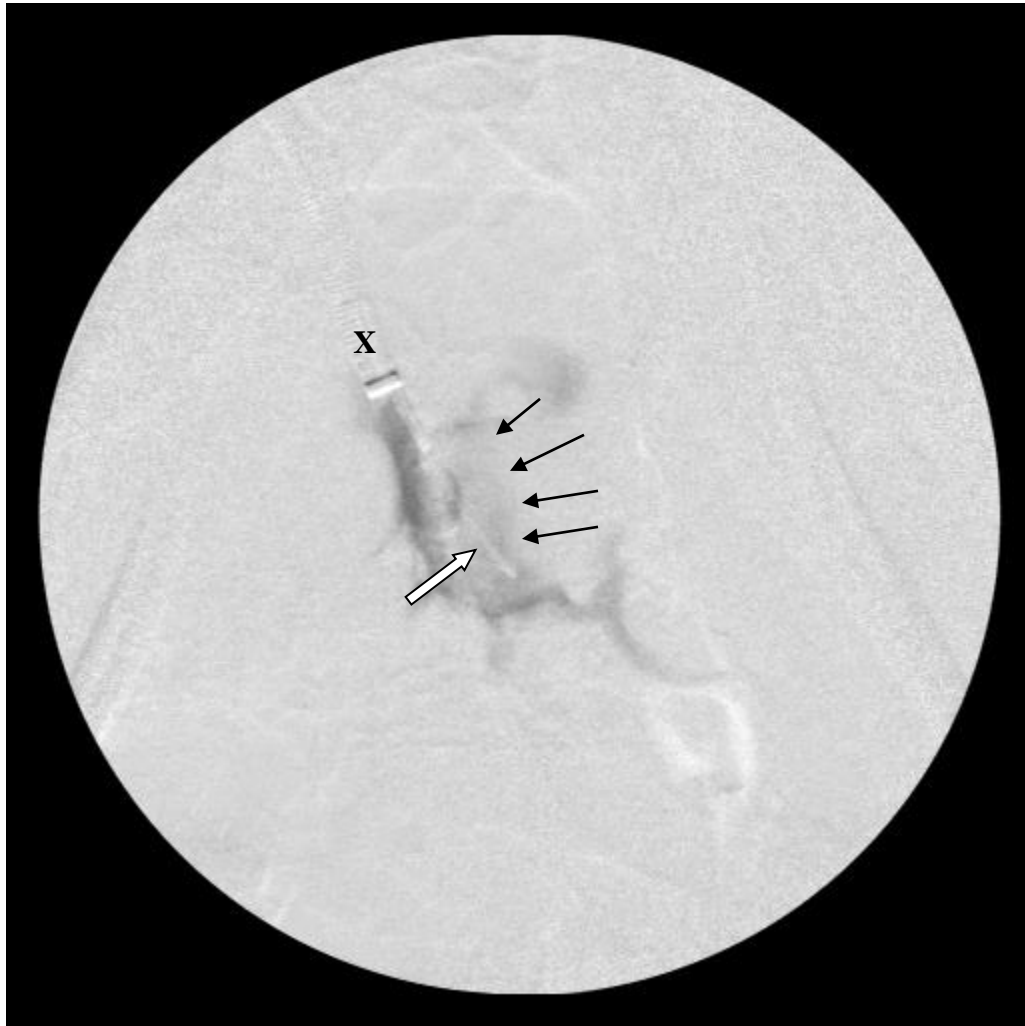

Figure 6.6 A dorso-ventral subtraction angiographic image of the cranium showing the catheter (X), needle placement within the pituitary gland (white arrow), “tumor blush” (delineated by arrows) around the needle, and extra contrast material filling the ventral cavernous sinus after injection.



6.4 RESULTS

The myeloscopic approach to the hypophysis was not successful. In each attempt hemorrhage prevented adequate visualization, despite flushing the endoscope with lactated Ringers solution, and the procedure was abandoned. It is possible that with further practice the technique could have been finessed, and certainly, the bleeding during endoscope placement has been previously reported (Prange et al. 2011b) and overcome.

The trans-sphenopalatine sinus approach failed due to a lack of appropriate instrumentation and anatomical variations between the horse and the human, upon which the technique had been based. Despite a very steep angle of the drill tract (rostro-lateral to caudomedial), passing through the rostral and caudal maxillary sinuses into the opening of the sphenopalatine sinus, the drill tip was still too rostral and the back of the sphenopalatine sinus could not be accessed. Further, the intimate proximity of the optic chiasm relative to the pituitary gland would have rendered this technic unfeasible.

The ventral trans-basisphenoidal osteotomy was reproducible and ablation of a portion (or all) of the pituitary gland was possible from this position using whichever method the surgeon might choose. After cadaveric success, the procedure was performed in a single live horse under a terminal anesthetic protocol. The procedure was performed as above, however, an error in the drill position resulted in inadvertent entry into the ventral cavernous sinus and uncontrollable hemorrhage. At this point the horse was humanely

euthanased by intravenous injection of Pentobarbitol^j into the jugular vein, without allowing it to recover from surgery.

In the 3 cadavers and 1 live, clinically normal, horse that underwent the minimally invasive transcatheter approach, access to the cavernous sinus and injection into the pituitary gland was possible and repeatable. Cut sections of the pituitary gland after minimally-invasive injection of methylene blue revealed intra-pituitary staining. A single aged mare with clinical signs consistent with PPID was subsequently subjected to the same procedure. Access to the cavernous sinus was achieved without complications but at postmortem examination it was clear that the needle had been directed slightly too far, with the result that the injected methylene blue had not entered the pituitary gland, but had been deposited into the cavernous sinus blood immediately caudal to the gland.

6.5 DISCUSSION

We report 4 surgical approaches to the equine pituitary gland, with the ventral trans-basisphenoidal osteotomy and the minimally-invasive transcatheter approaches showing promise for the potential treatment of equine PPID. A surgical method to access the equine pituitary gland may allow surgical resection or chemical ablation of abnormal pars intermedia tissues, thereby controlling clinical signs of PPID in affected horses and avoiding daily oral medications.

The treatment of pituitary tumors in humans is most often multimodal and encompasses, microsurgical, radiosurgical, radiation and medical treatments. Endonasal surgical approaches to the skull base (microscopic or endoscopic), and in particular the transsellar approach to the pituitary gland, have been well described (Joshi and Cudlip 2008; Miller et al. 2014). Despite the endoscopic approach gaining traction there is, as yet, no firm consensus on whether the microscopic or endoscopic technique is superior (Jane et al. 2005; Kasemsiri et al. 2014; Cappabianca et al. 2014). In either case, a profound knowledge of the anatomical relationships in the skull base region is required (Budu et al. 2013).

The pituitary gland of the herbivorous quadrupeds lies ventral in the cranium within the hypophyseal fossa of the sella turcica. It is surrounded by the ventral cavernous sinus into which both pars distalis hormones and POMC-derived peptides from the pars intermedia are secreted. The comparatively long nasal passages and large paranasal sinuses of the horse, as well as the anatomical difference in the position of the hypophysis compared to humans, makes surgical access through the equine sphenopalatine sinus extremely difficult. As illustrated in Figure 6.1, the surgical approach is complicated by the position of the optic chiasm which lies directly between the caudal extent of the air-filled sinus and the rostral margin of the hypophysis. Even if the surgeon were to manage to position the osteotomy ventral to the optic chiasm, they would inevitably enter the rostral portion of the blood-filled ventral cavernous sinus which would result in significant hemorrhage.

The nasal passage issue has been overcome in the dog by utilizing an oral approach and computed tomographic guidance (Mamelak et al. 2014). Unfortunately, the horse mouth does not open wide enough to permit use of this technique and a modification (the ventral trans-basisphenoidal osteotomy) was devised for use in the horse. It was technically demanding requiring competent use of the flexible endoscope, laser and neurosurgical skills. Accurate positioning was absolutely critical so as not to miss the hypophysis and enter the surrounding vascular sinus spaces. Use of a stereotactic frame as well as advanced image guidance such as the STEALTH neurosurgical imaging and surgical navigation system^k as used in human surgery would have greatly aided in technique development and may have improved success rates. However, it is cost prohibitive at the current time. Additional possible surgical complications are associated with damage to the vessels and nerves of the guttural pouch through which the basisphenoid bone is accessed. Guttural pouches are a diverticulum of the auditory tube, present in Perissodactyls (e.g., equine, tapir, rhinoceros) and other species (Brandt 1863; Hinchcliffe and Pye 1969). In the horse, it occupies the space extending from the roof of the pharynx to the base of the skull and from the atlanto-occipital joint to the pharyngeal recess. Each pouch has a volume of 300 to 500 mL and is divided into a medial and lateral compartment by its reflection of the mucosal lining around the dorsal, lateral and medial surfaces of the stylohyoid bone. The pouches are so large that they are joined at their rostro-medial aspects, forming a medial septum. The unique shape of the guttural pouch is created by myriad structures to which it is physically attached and encompasses 10 arteries, 5 cranial nerves, 7 muscles, as well as lymph nodes, the parotid salivary gland, bones of the skull and mandible, and adipose tissue.

There are multiple reported surgical approaches to the guttural pouch. The hyovertebrotomy, also known as the Dorsal approach and Dieterich's Method, (McIlwraith and Turner 1987), access via Viborg's triangle (McIlwraith and Turner 1987), the Whitehouse and modified Whitehouse approaches, also known as the Ventral approach or the Sand's method, (McAllister 1978; Freeman 1992) and the Garm method (Garm 1946). Irrespective of the chosen approach the most common surgical complication is intractable dysphagia, which can lead to aspiration pneumonia and death (Freeman 1990). Despite this, the ventral trans-laryngeal approach to the midline of the basisphenoid bone was considered to present the least risk because of the relatively atraumatic nature of the laparoscopic cannula placement and the added benefit of soft tissue protection during the creation of the osteotomy as the drill was contained within the laparoscopic cannula.

Interventional radiology is defined as a “therapeutic and diagnostic specialty that comprises a wide range of minimally invasive image-guided therapeutic procedures as well as invasive diagnostic imaging” (Society of Interventional Radiology 2010). In the head and neck, this technique can be used (amongst others) for tumor embolization, occlusion of vascular malformation such as arterio-venous fistulas, treatment of aneurysms, radiofrequency ablation and cryoablation of tumors and venous sampling, specifically of hormonal output to predict successful treatment intra-and post-surgery (Yen et al. 2008; Broomfield et al. 2009; Jindal et al. 2012).

Interventional radiology is used in equine surgery for the embolization of the internal carotid, external maxillary or major palatine arteries in cases of guttural pouch mycosis. A mechanical device, such as a balloon catheter (Freeman and Donawick 1980) or thromboembolic coils (Matsuda et al. 1998; Lepage and Piccot-Crézollet 2005; Benredouane and Lepage 2012) are subsequently used to occlude the offending vessel. Similar treatment of a palatine artery pseudoaneurysm with right sided epistaxis has also been reported (McLellan et al. 2014).

The internal carotid artery passes through the guttural pouch on the caudo-medial wall, enters a sigmoid curve and then the cranium via the foramen lacerum. It then gives rise to the rostroventral infundibular (hypophyseal) arteries supplying the ventral capillary network of the median eminence of the hypothalamus (Vitums 1975). Ventral and dorsal hypophyseal vessels descend through the pars tuberalis to supply blood to the distal part of the adenohypophysis terminating in the sinusoidal network of the pars distalis. The right and left caudal infundibular arteries arise from the caudal intercarotid artery and, in some cases, the internal carotid artery, and running in a sheath of dura mater, pass through the intercavernous sinus to become a capillary network in the most distal aspect of the pars nervosa and infundibular stalk. Passage of a guide wire and catheter beyond the internal carotid artery junction with the rostroventral infundibular artery has not proven possible in our cadaveric work due to the acute angle and tortuous nature of this junction (data not shown). A transarterial approach to the pituitary gland to deliver either coils, particles (such as polyvinyl alcohol, embospheres or gelfoam) or liquid embolics

(Jindal et al. 2012) into the direct arterial supply of the pars intermedia and thus spare the remainder of the gland from damage was initially envisioned, but could not be realized.

There are two paths of venous drainage; caudoventrally into the ventral petrosal sinus and foramen lacerum and secondly, rostrolaterally into the ophthalmic vein and the deep facial vein (Vitums, 1978). This latter path was exploited for long-term sampling of pituitary effluent blood (Irvine et al. 1984; Irvine et al. 1987; Alexander et al. 1996). Use of a minimally invasive transvenous approach, as outlined above, to access the pituitary gland in the horse cadavers of this report was successful and repeatable. It allowed the passage of a long flexible needle through the introducer sheath in isolated heads and in the live anaesthetized horses, under fluoroscopic guidance, to access and inject dye into the pituitary gland.

Sakes et al. (2015) published on the use of a motorized resector to partially ablate the gland using this transvenous access route, however, the future vision is that a neurolytic (such as ethylalcohol, or glycerol) or a melanotroph-specific targeting agent (Lau et al. 2015; Kaiser 2015) could be injected under guidance and result in partial ablation of the pituitary gland. In advanced stages of disease the proportion of the gland that is represented by the pars intermedia would be much greater (Leitenbacher and Herbach 2016) and thus the majority of damage caused would be directed at the offending portion of the hypophysis, however, it is likely that collateral damage to the pars nervosa or the pars distalis may also occur. The degree of lysis or ablation of the pars intermedia required to return the horse to clinical normalcy is unknown. The aim would not be to

completely deprive the horse of the hormone output of the pars intermedia, but merely to disable a sufficient amount of this specific region as to improve the quality of life of these aged horses.

In conclusion, of all the surgical approaches developed to access the equine hypophysis, the transvenous approach to the ventral cavernous sinus of the cranium using interventional radiology is the least invasive. It is repeatable and, other than fluoroscopy, requires the least expensive equipment and arguably is least complicated. Further work is needed to determine which method of ablation is most effective, and how much can be ablated while preserving the critical homeostatic mechanisms of the gland. While hormone supplementation is simple and easy to use in human medicine after tumor ablation, anything other than complete resolution of clinical signs will be unsuitable in the horse because there is already an oral daily medication for PPID.

Footnotes:

^a Olympus GIF-XP160, Olympus Corporation, Philadelphia, USA.

^b DiodeVet, Newark, Delaware, USA.

^c Versaport™ Plus, Bladeless trochar, Medtronic, Minneapolis, MN, USA

^d OEC 9900 Elite Cardiac C-Arm; GE Healthcare, Inc.; Salt Lake City, UT, USA

^e Swan Ganz, Edwards Lifesciences LLC, Irvine, CA, USA

^f Omnipaque; GE Healthcare, Inc.; Princeton, NJ, USA

^g Straight wire guide; TSF-38-145; Cook Medical, Inc.; Bloomington, IN, USA

^h Angled introducer sheath ; KCFW-8.0-18/38-45-RB-ANL1-HC; Cook Medical, Inc.;
Bloomington, IN, USA

ⁱ Transseptal needle; TSNC-19-56.0 Cook Medical, Inc.; Bloomington, IN, USA

^j Pentobarbital sodium; Euthanyl Forte, Bimeda-MTC Animal Health Inc., Cambridge,
ON, Canada.

^k StealthStation S7 Surgical Navigation System, Medtronic, Minneapolis, MN, USA

6.6 REFERENCES

Alexander SL, Irvine CHG, Donald RA. Short-term secretion patterns of corticotropin-releasing hormone, arginine vasopressin and ACTH as shown by intensive sampling of pituitary venous blood from horses. *J Neuroendocrinol* 1994; 60: 225-236.

Alexander SL, Irvine CHG, Donald RA. Dynamics of the regulation of the hypothalamo-pituitary-adrenal (HPA) axis determined using a nonsurgical method of collecting pituitary venous blood from horses. *Front Neuroendocrinol* 1996; 17: 1-50.

Allen JR, Barbee DD, Boulton CR et al. Brain abscess in a horse: Diagnosis by computed tomography and successful surgical treatment. *J Am Vet Med Assoc* 1987; 19: 552-555.

Benredouane K, Lepage O. Trans-arterial coil embolization of the internal carotid artery in standing horses. *Vet Surg* 2012; 41: 404-409.

Biller BMK, Grossman AB, Stewart PM et al. Treatment of adrenocorticotropin-dependent Cushing's syndrome: A consensus statement. *J Clin Endocrinol Metab* 2008; 93: 2454-2462.

Bons J, Cornips E, Zwam W van et al. ACTH measurements during surgery for Cushing's disease: a feasibility study. NVKC Voorjaarscongres. Veldhoven, the Netherlands. 9-11 April 2014.

Brandt JF. Bericht über eine Abhandlung, Untersuchung der Gattung Hyrax in anatomischer und verwandtschaftlicher Beziehung. Bulletin of the Academy of Imperial Science (St. Petersburg) 1863; 5: 508-510.

Broomfield S, Bruce I, Birzgalis A et al. The expanding role of interventional radiology in head and neck surgery. J R Soc Med 2009; 102: 228-234.

Budu V, Mogoanta CA, Fanuta B et al. The anatomical relations of the sphenoid sinus and their implications in sphenoid endoscopic surgery. Rom J Morphol Embryol 2013; 54: 13-16.

Cappabianca P, Cavallo LM, Solari D et al. Endoscopic endonasal surgery for pituitary adenomas. World Neurosurgery 2014; 82: S3-S11.

Cornelisse CJ, Schott HC, Lowrie CT et al. Successful treatment of intracranial abscesses in 2 horses. J Vet Intern Med 2001; 15: 494-500.

Edwards GB and Greet T. Disorders of the guttural pouches (Auditory tube diverticuli). In: Equine respiratory medicine and surgery. McGorum BC, Dixon PM, Robinson NE and Schumacher J Eds. Elsevier Saunders, St. Louis, Missouri USA. 2007; 419-436.

Freeman DE. Guttural pouch. In: Equine Surgery. JA Auer (ed.), W.B. Saunders, Philadelphia. 1992; 480-488.

Freeman D, Donawick WJ. Occlusion of internal carotid artery in the horse by means of a balloon-tipped catheter: Clinical use of a method to prevent epistaxis caused by guttural pouch mycosis. *J Am Vet Med Assoc* 1980; 176: 236-240.

Fulton IC, Anderson BH, Stick JA et al. Larynx. In: *Equine Surgery* 4th Edn. Auer JA and Stick JA Eds. Elsevier Saunders, St. Louis, Missouri USA. 2012; 592-623.

Garm O. Luftposeempeymer og deres behandling. *Skand. Vet. Tidskr* 1946; 26: 401-423.

Hinchcliffe R, Pye A. Variations in the middle ear of the mammalia. *J Zool. (London)* 1969; 157: 277-288.

Irvine CHG, Alexander SL. A novel technique for measuring hypothalamic and pituitary hormone secretion rates from collection of pituitary venous effluent in the normal horse. *J Endocrinol* 1987; 113: 183-192.

Irvine CH, Hunn R. Long term collection of pituitary venous blood in the unrestrained horse. *NZ Med J* 1984; 97: 735.

Jane JA, Han J, Prevedello DM et al. Perspectives on endoscopic transsphenoidal surgery. *Neurosurg Focus* 2005; 19(6): E2, 1-10.

Janicek JC, Kramer J, Coates JR et al. Intracranial abscess caused by *Rhodococcus equi* infection in a foal. J Am Vet Med Assoc 2006; 228: 251-253.

Jindal G, Gemmete J, Gandhi D. Interventional neuroradiology: Applications in otolaryngology, head and neck surgery. Otolaryngol Clin N Am 2012; 45: 1423-1449.

Joshi SM, Cudlip S. Transsphenoidal surgery. Pituitary 2008; 11: 353-360.

Kaiser UB. Cushing's disease: towards precision medicine. Cell Res 2015; 25: 649-650.

Kasemsiri P, Carrau RL, Ditzel Filho LF et al. Advantages and limitations of endoscopic endonasal approaches to the skull base. World Neurosurgery 2014; 82: S21-S21.

Kramer J, Coates J, Hoffman AG et al. Preliminary anatomic investigation of three approaches to the equine cranium and brain for limited craniectomy procedures. Vet Surg 2007; 36: 500-508.

Lau D, Rutledge C, Aghi MK. Cushing's disease: current medical therapies and molecular insights guiding future therapies. Neurosurg Focus 2015; 38: E11

Leitenbacher J, Herbach N. Age-related qualitative histological and quantitative stereological changes in the equine pituitary. J Comp Path 2016; 154: 215-224.

Lepage O, Piccot-Crézollet C. Transarterial coil embolization in 31 horses (1999-2002) with guttural pouch mycosis: a 2-year follow-up. *Equine Vet J* 2005; 37: 430-434.

Locatelli A. Destruction in-situ of the horse pituitary-gland by laser ray. *Bulletin de l'Académie vétérinaire de France* 1984; 57: 171-176.

Mamelak AN, Owen TJ, Bruyette D. Transsphenoidal surgery using a high definition video telescope for pituitary adenomas in dogs with pituitary dependent hypercortisolism: Methods and results. *Vet Surg* 2014; 43: 369-379.

Matsuda Y, Nakanishi Y, Mizuno Y. Occlusion of the internal carotid artery by means of microcoils for preventing epistaxis caused by guttural pouch mycosis in horses. *J Vet Med Sci* 1998; 61: 221-225.

McAllister ES. Guttural pouch disease. In: *Proc Ann Convention of AAEP* 1978; 23: 251-258.

McFarlane D. Equine pituitary pars intermedia dysfunction. *Vet Clin Equine* 2011; 27: 93-113.

McIlwraith CW, Turner AS. *Equine Surgery: Advanced Techniques*. Philadelphia: Lea & Febiger, 1987; 228-238.

McClellan NR, Mudge MC, Scansen BA et al. Coil embolization of a palatine artery pseudoaneurysm in a gelding. *Vet Surg* 2014; 43: 487-494.

Meiji BJ, Voorhout G, van den Ingh TS et al. Results of transsphenoidal hypophysectomy in 52 dogs with pituitary-dependent hyperadrenocorticism. *Vet Surg* 1998; 27: 246-261.

Miller BA, Ioachimescu AG, Oyesiku NM. Contemporary indications for transsphenoidal pituitary surgery. *World Neurosurgery* 2014; 82: S147-S151.

Millington WR, Dybdal NO, Dawson R et al. Equine Cushing's disease: differential regulation of β -endorphin processing in tumors of the intermediate pituitary. *J Endocrinol* 1988; 123: 1598-1604.

Prange T, Carr E, Stick JA et al. Endoscopic anatomy of the cervical vertebral canal in the horse: A cadaver study. *Equine Vet J* 2011a; 43: 317-323.

Prange T, Derksen FJ, Stick JA et al. Cervical vertebral canal endoscopy in the horse: Intra- and post-operative observations. *Equine Vet J* 2011b; 43: 404-411.

Prange T, Carr E, Stick JA et al. Cervical vertebral canal endoscopy in a horse with cervical vertebral stenotic myelopathy. *Equine Vet J* 2012; 44: 116-119.

Sakes A, Arkenbout EA, Jelínek F et al. Design of an endovascular morcellator for the surgical treatment of equine Cushing's disease. *Vet Q* 2015; 35: 165-169.

Society of Interventional Radiology. Global statement defining interventional radiology. *J Vasc Interv Radiol* 2010; 21: 1147-1149.

van der Kolk JH, Heinrichs M, van Amerongen JD et al. Evaluation of pituitary gland anatomy and histopathologic findings in clinically normal horses and horses and ponies with pituitary pars intermedia adenoma. *Am J Vet Res* 2004; 65: 1701-1707.

Vanschandevijl K, Gielen I, Nollet H et al. Computed tomography-guided brain biopsy for in-vivo diagnosis of a cholesterinic granuloma in a horse. *J Am Vet Med Assoc* 2008; 233: 950-954.

Vitums A. Observations on the equine hypophyseal portal system. *Anat, Histol, Embryol* 1975; 4: 149-161.

Vitums A. Development of venous drainage of equine hypophysis cerebri. *Anat, Histol, Embryol* 1978; 7: 120-128.

Yen TW, Wang TS, Doffek KM et al. Reoperative parathyroidectomy: an algorithm for imaging and monitoring of intraoperative parathyroid hormone levels that results in a successful focused approach. *Surgery* 2008; 144: 611-619.

CHAPTER 7

GENERAL DISCUSSION

7.1 INTRODUCTION

Equine pituitary pars intermedia dysfunction (PPID), also known as equine Cushing's disease, is a common endocrine disease of older horses (Orth et al. 1982; Schott 2002). The condition is associated with an enlargement of the pars intermedia of the pituitary gland. Initially reported as a neoplasm, an adenoma, it is now known that the hyperplasia and hypertrophy of this selective region of the pituitary gland is due to a lack of dopaminergic inhibition from the hypothalamus (McFarlane 2007). The abnormal cells produce high levels of hormone which lead to a number of clinical signs. The most readily detected is hypertrichosis, which often leads the owner to seek veterinary attention (McFarlane 2011; Schott et al. 2017). A diagnosis is usually made by performing a laboratory test after clinical examination. There are several test options, however, none are of high enough specificity and sensitivity to be categorized as a definitive antemortem test.

Despite advances in the understanding of the pathophysiology of PPID, the treatment, which was first described in the 1980s – the daily, lifelong, oral administration of pergolide mesylate, a dopamine receptor agonist – is still the most widely used therapy that the veterinary profession has to offer. The caveat in the development of a new treatment is that it must be as least as good as, if not better than, the current treatment.

This means that the dosing interval must be less frequent than every day, and ideally, a single application. Theoretically, pituitary ablation *in-toto*, as occurs for treatment of this condition in the dog (Meij 1997), or in part, as occurs in cases of human pituitary enlargement (Krisht 2002; Cappabianca 2004) may be a useful treatment option. Given the myriad hormones produced by the pituitary gland, most of which appear unaffected by PPID, *in-toto* removal is questionable in the horse, leaving researchers to develop a selective ablative procedure.

7.2 GENERAL RESULTS AND FUTURE STUDIES

The long term goal of this research was to explore the feasibility of developing a targeted tissue-specific approach for the treatment of equine PPID. This thesis constitutes a first approach to this goal.

The first specific aim, to confirm the need for this advanced therapy by determining the prevalence of PPID in horses globally, was achieved using an international online survey of over 400 veterinarians in 20 countries (Chapter 2). It showed that 84% of respondents had at least 1 horse with PPID under their care, with half of the veterinarians reporting at least 5 horses with PPID. The estimated prevalence of PPID was approximately 1%, which is consistent with other reports, and there was no apparent geographical variation. This data showed that most veterinarians servicing the horse industry have to deal with this chronic, debilitating problem. Importantly, respondents indicated that the cost of the current treatment and management limitations surrounding its use meant that they would

be interested in pursuing novel treatment options if they became available. Further, as the life-span of domestic horses is increasing, the prevalence of this condition should rise, creating more of a need for an alternative therapy. Limitations of online data collection, and surveys in particular, are many; however, it is the author's opinion that the need for treatment of this condition is now without question.

The second specific aim of this thesis was to continue the investigation of the underlying cellular mechanism of PPID by sequencing the POMC, PC1 and PC2 genes, identifying a suitable internal control gene for use in the equine pituitary gland, examining gene expression of pro-hormone convertases, and quantifying the differences in POMC, ACTH, α MSH and CLIP hormone concentrations in affected and unaffected horses. Our laboratory investigations (Chapter 3) determined that YWHAZ was the best internal house-keeping gene for the equine pituitary gland. Comparisons to this gene indicated that in horses with PPID, POMC mRNA expression are increased dramatically. Additionally, we found that upregulation of PC1 and PC2 also occurs. PC1 and PC2 upregulation had previously been hypothesized to occur in PPID horses, based on murine models lacking the dopamine type-2 receptor (Saiardi 1998). Interestingly, we found a similar magnitude of upregulation between the 2 types of pro-hormone convertases, which differs from the murine study. This may have been due to the fact that we were dealing with horses suffering from a naturally occurring disease versus a genetically modified laboratory rodent model or a factor of the method of sample collection. Additionally, as the degree, or severity, of PPID varies within and between individuals, it

is possible that the low number of horses used in this experiment precluded the ability to determine differential upregulation. Irrespective of the cause, the theorized upregulation of PC1 and PC2 has now been demonstrated in the horse. Finally, we determined a partial sequence for the equine POMC gene as well as for PC1 and PC2. Prior to this, only predicted sequences were available in GenBank. The next steps in this research, if we are to develop tissue and, or, molecular therapeutic targets for PPID, is to definitively identify the ACTH variant responsible for the clinical syndrome. This may allow us to identify horses in the prodromal phase of the disease (a definitive antemortem test), leading to earlier treatment and prolonging the useful life and welfare of the horse; or to specifically target the melanotrophs producing this variant. We know that treatment with a dopamine agonist normalizes the circulating levels of ACTH, and the clinical signs of disease (Donaldson et al. 2002; Perkins et al. 2002) but other possible medical options exist. These include L-deprenyl and BIM-23A760. L-deprenyl is a MOA-B inhibitor which acts to prolong the effect of dopamine by reducing breakdown in the synaptic cleft (Bruyette et al. 1997). BIM-23A760 is a chimeric compound that has both somatostatin and dopamine elements allowing it to bind to both types of receptors (sstr2 and D2R) resulting in potent suppression of growth hormone and prolactin in human studies (Colao et al. 2011). Local delivery of chemotherapeutic agents such as carboplatin microspheres is also a possibility (Chen and Lu 1999). Further, identifying cell-specific markers, such as surface epitopes, could allow the development of selective targeting agents to destroy the abnormal melanotroph cell-lines. Examples of these include pituitary tumor-derived fibroblast growth factor receptor-4 (ptd-FGFR4) and specific-specific variants of human

sperm protein 17 (Sp17), which have been shown to be upregulated and expressed on the cell-surface of human pituitary tumors (Asa and Ezzat 2005; Grizzi et al. 2012).

The third specific aim of this thesis was to investigate the methodology for site-specific application of future therapy for equine PPID; essentially to find a mechanism by which future agents could be delivered (Chapters 4, 5, and 6). Imaging the brain is complicated in any species as it is surrounded by dense bone. Imaging the equine brain is further complicated by the size of the animal, which necessitates modifications to standard equipment, or specially designed, and thus expensive, dedicated imaging modalities. Options for visualizing the brain include magnetic resonance imaging (MRI) and computed tomography (CT). The former is superior in terms of soft tissue interpretation, however, access to a 3 Tesla magnet with a bore size big enough for a horse is limited. Additionally, the MRI acquisition times are substantially longer than those needed for CT imaging. CT is not as good as MRI for the interpretation of soft tissue structures, however, by using contrast enhancement the margins of the pituitary gland can be delineated when imaged using this methodology (Pease et al. 2011). CT is more widely available and thus we elected to develop a highly specific low-volume contrast enhancement technique for the equine brain. We reported that the low-volume intraarterial administration method was as good at contrast enhancement as the previously published high-volume intravenous method and substantially less expensive. The vision was that CT, using contrast enhancement, could be used as an adjunctive diagnostic tool, in addition to guiding the surgical ablation, or targeted delivery of a melanotroph-specific

agent to the pars intermedia. Ultimately, however, as our surgical methodology evolved, we used standard human interventional radiology techniques. These typically use contrast-enhanced fluoroscopy as the standard method of guidance. Fluoroscopy is highly versatile. In an equine situation, the portability of the system allows for the unit to be moved into the operating room. Many different sizes of patient and positions on the surgical table can be accommodated. Different imaging planes can be obtained, with newer units having resolution equivalent to CT, and the relatively rapid acquisition times and real-time nature of the image allow for accurate placement of instruments within the patient.

Given that access to the pituitary gland in the horse will most likely be performed under general anesthesia, the effect of general anesthesia on ACTH production was performed. Any such changes would have to be taken into account if intra-operative measurements of local ACTH concentration are to be used as a marker of the degree of pars intermedia ablation, or success of targeted delivery, during surgery (Bons et al 2014). We found that ACTH concentration of the blood in the ventral cavernous sinus, and the pulsatility of the hormone release, was reduced under general anesthesia.

Finally, 4 surgical methods were attempted in cadavers (heads) and as a terminal procedure in live horses, with the intention of accessing the pituitary gland. The myeloscopic and trans-sphenopalatine sinus approaches were not successful in our hands because of bleeding, and a failure to obtain the correct angle of approach, respectively. However, the trans-basisphenoid and minimally invasive trans-venous approach were

promising. Without advanced intra-operative guidance in the form of a stereotactic frame or a commercial neurosurgical guidance system, the former technique was not as repeatable, nor as minimally invasive, as the trans-venous approach to the ventral cavernous sinus of the brain. The trans-venous approach fulfilled our aim of gaining access to the pituitary gland and is an exciting advance that may allow for the development of a technique to effect a long-term cessation of clinical signs of disease, and thus improve the welfare of the horse.

7.3 CONCLUSIONS

In conclusion, we have demonstrated there is a need for an alternative therapy for PPID; we continued to build on the understanding of the underlying mechanisms of disease; and we developed a repeatable method of accurately delivering the tissue and, or, molecular therapeutic agents of the future.

7.4 REFERENCES

Asa SL, Ezzat S. Genetics and proteomics of pituitary tumors. *Endocrine* 2005; 28: 43-47.

Bons J, Cornips E, Zwam W van, et al. ACTH measurements during surgery for Cushing's disease: a feasibility study. NVKC Voorjaarscongres. Veldhoven, the Netherlands. 9-11 April 2014

Bruyette DS, Ruehl WW, Entriken T et al. Management of canine pituitary-dependent hyperadrenocorticism with 1-deprenyl (anipryl). *Vet Clin N Am Sm Anim Pract* 1997; 27: 273-286.

Cappabianca P, Cavallo LM, de Divitiis E. Endoscopic endonasal transsphenoidal surgery. *Neurosurg.* 2004; 55: 933-941.

Chen W, Lu DR. Carboplatin-loaded PLGA microspheres for intracerebral injection: formulation and characterization. *J Microencapsulation* 1999; 16: 551-563.

Colao A, Grasso LFS, Pivonello R et al. Therapy of aggressive pituitary tumors. *Expert Opin. Pharmacother* 2011; 12: 1561-1570.

Donaldson MT, LaMonte BH, Morresey P et al. Treatment with pergolide or cyproheptadine of pituitary pars intermedia dysfunction (equine Cushing's disease). *J Vet Intern Med* 2002; 16: 742-746.

Grizzi F, De Ieva A, Di Biccari S et al. Sperm protein 17: Is it a useful target antigen in human pituitary adenomas? *Procedia in Vaccinology* 2012; 6: 39-46.

Krisht AF. The trans-sphenoid approach and its variants. *Contemp Neurosurg.* 2002; 24: 654-660.

McFarlane D. Advantages and limitations of the equine disease, pituitary pars intermedia dysfunction as a model of spontaneous dopaminergic neurodegenerative disease. *Ageing Res Rev* 2007; 6: 54-63.

McFarlane D. Equine pituitary pars intermedia dysfunction. *Vet Clin Equine* 2011; 27: 93-113.

McFarlane D, Dybdal N, Donaldson MT, et al. Nitration and increased alphasynuclein expression associated with dopaminergic neurodegeneration in equine pituitary pars intermedia dysfunction. *J Neuroendocrinol* 2005; 17: 73-80.

Meij BP, Voorhout G, van den Ingh T et al. Transphenoidal hypophysectomy in Beagle dogs: Evaluation of a microsurgical technique. *Vet Surg.* 1997; 26: 295-309.

Orth DN, Holscher MA, Wilson MG et al. Equine Cushing's disease: plasma immunoreactive proopiomelanocortin peptide and cortisol levels basally and in response to diagnostic tests. *Endocrinol* 1982; 110: 1430-1441.

Pease AP, Schott II HC, Howey EB et al. Computed tomographic findings in the pituitary gland and brain of horses with pituitary pars intermedia dysfunction. *J Vet Intern Med* 2011; 25: 1144-1151.

Perkins GA, Lamb S, Erb HN et al. Plasma adrenocorticotropin (ACTH) concentrations and clinical response in horses treated for equine Cushing's disease with cyproheptadine or pergolide. *Equine Vet J* 2002; 34: 679-85.

Saiardi A, Borrelli E. Absence of dopaminergic control on melanotrophs leads to Cushing's-like syndrome in mice. *Mol Endocrinol* 1998; 12: 1133-1139.

Schott HC. Pituitary pars intermedia dysfunction: Equine Cushing's disease. *Vet Clin Equine* 2002; 18: 237-270.

Schott HA, Marteniuk JV, Miller R et al. Reliability of a clinical scoring system for PPID. In: *Proc Int Eq Endocrinol Summit (Havemeyer Foundation)*. 2017; 15.

APPENDIX A

PAPER AND ONLINE QUESTIONNAIRE CIRCULATED TO DETERMINE VETERINARIAN APPROACH TO DIAGNOSIS, MANAGEMENT AND REPORTED PREVALENCE

1. Do you currently have a horse (or horses) in your practice with PPID (equine Cushing's disease)? If your answer is "No," please skip to question 11.

- Yes
- No

2. Approximately how many horses do you have with this problem and what percentage of your equine patients have this condition ? (2 answers please).

3. What is the approximate mean (average) age of these horses?

4. How was the diagnosis made (in most cases)? Check as many as necessary.

- Clinical signs alone
- Clinical signs and endogenous ACTH concentration
- Clinical signs and a dexamethasone suppression test
- Clinical signs and an ACTH stimulation test
- Clinical signs and combined dexamethasone suppression / TRH stimulation test
- Other (please specify):

5. Are you treating these horses for the primary disease process (pituitary dysfunction or pituitary tumor)? If your answer is "No," then please skip to Question 8.

- Yes
- No

6. Collectively, how are you treating these horses?

- Benign neglect / monitoring
- Medically
- Other (please specify):

7. What medical treatments are you using (check all that apply)? Please skip to Question 11 after completing this question.

- Commercial pergolide mesylate
- Compounded pergolide
- Commercial bromocriptine mesylate
- Commercial trilostane
- Commercial cyproheptadine
- Other (please specify):

8. If you are not treating these horses, why not?

- Client limitations
- Drugs not available
- Treatment not warranted
- Other (please specify):

9. If client limitations prevent treatment, why?

- Financial limitations
- Management limitations (cannot treat as recommended)
- Other (please specify):

10. If treatment is not warranted, why?

- Age of horse
- Disease not deemed to be of concern (by client or veterinarian)
- Other (please specify):

11. Do you perceive this disease to be an important equine health issue?

- Yes
- No

Please provide additional comments below if necessary:

12. Do you think that we need a new way to treat (or cure) this disease?

- Yes
- No

Please provide additional comments below if necessary:

13. Which of the following best describes your practice situation?

- Private practice
- Academia
- Government institution
- Military
- Other (please specify):

14. Which of the following best describes your practice focus?

- Equine only / speciality
- Large animal (equine predominant)
- Large animal (general)
- Small animal / equine
- General mixed practice
- Other (please specify):

15. Please provide your COUNTRY of practice (analysis of prevalence by country will be performed)

APPENDIX B

LIST OF GENERAL AND EQUINE VETERINARY MEDICAL GROUPS PASSING THE SURVEY LINK TO THEIR EMAIL LISTS, POSTED A LINK ON THEIR WEB PAGES OR SENDING THE LINK IN NEWSLETTERS.

CVMA-	Canadian Veterinary Medical Association
OVMA-	Ontario Veterinary Medical Association
SVMA-	Saskatchewan Veterinary Medical Association
ABVMA-	Alberta Veterinary Medical Association
OMVQ-	Ordre des médecins vétérinaires du Québec
NSVMA-	Nova Scotia Veterinary Medical Association
AAEP-	American Association of Equine Practitioners
	American Board of Veterinary Practitioners
	American College of Veterinary Internal Medicine- List Server
	European College of Veterinary Internal Medicine- List Server
	Oklahoma Veterinary Medical Association
BEVA-	British Equine Veterinary Association
GPM-	German Equine Veterinary Association
AVEF-	Association Veterinaire Equine Francaise
AVME (Portugal)-	Associação de Médicos Veterinários de Equinos
AVEEC-	Associacio de Veterinaris Especialistes en Equids de Catalunya
SIVE-	Società Italiana Veterinari per Equini
	Norwegian Association of Horse Practitioners
	Swedish Equine Veterinary Association
NZEVA –	New Zealand Equine Veterinary Association

AEVA – Australian Equine Veterinarian Association
VSBT- Veterinary Surgeons' Board of Tasmania
VSBWA Veterinary Surgeons' Board of Western Australia
SAEVA – South African Equine Veterinarian Association
Chilean Association of Equine Veterinarians
RCVS Charitable Trust
VetsOnline
VIN.com
vetsurgeons.org
thehorse.com
Mark Andrews Equine Science Updates